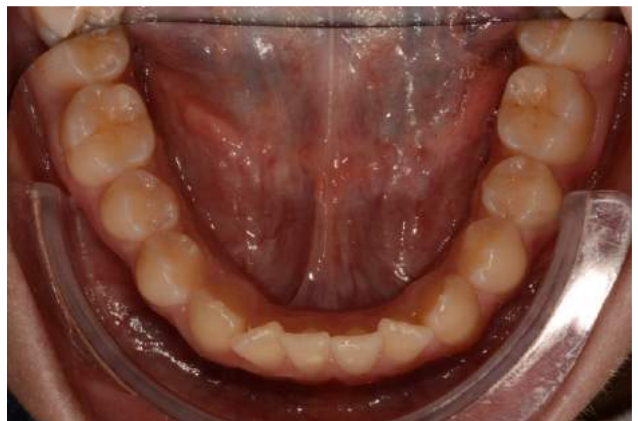
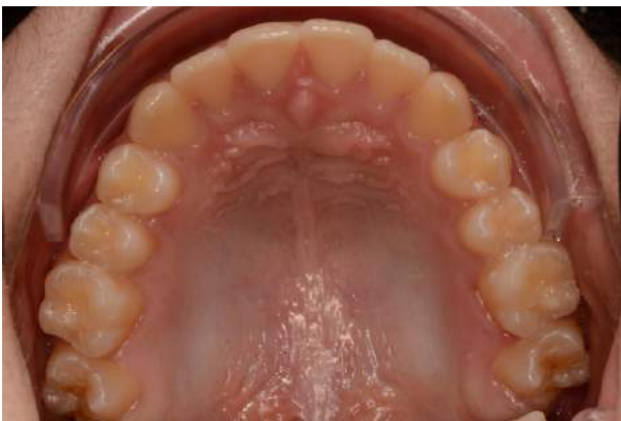
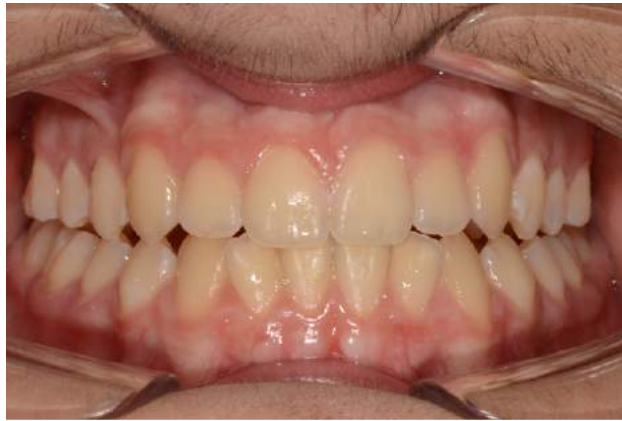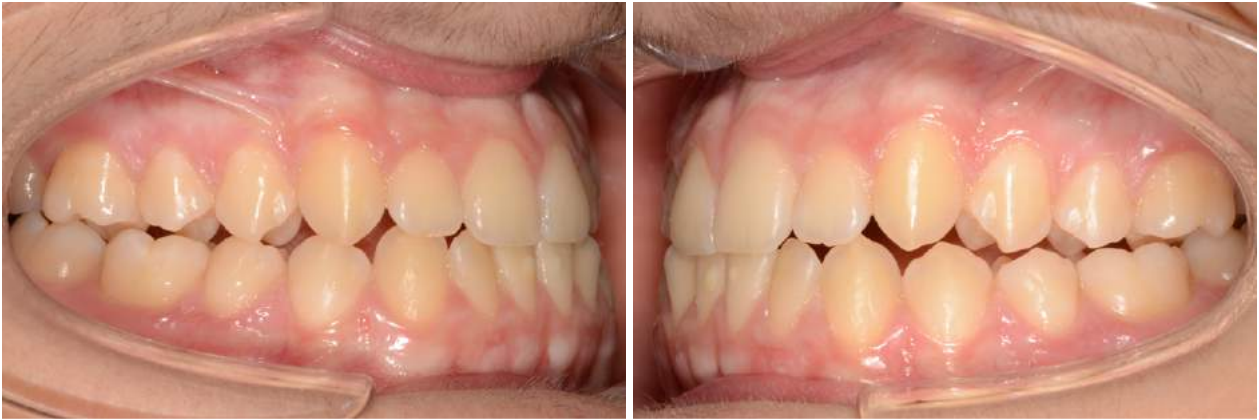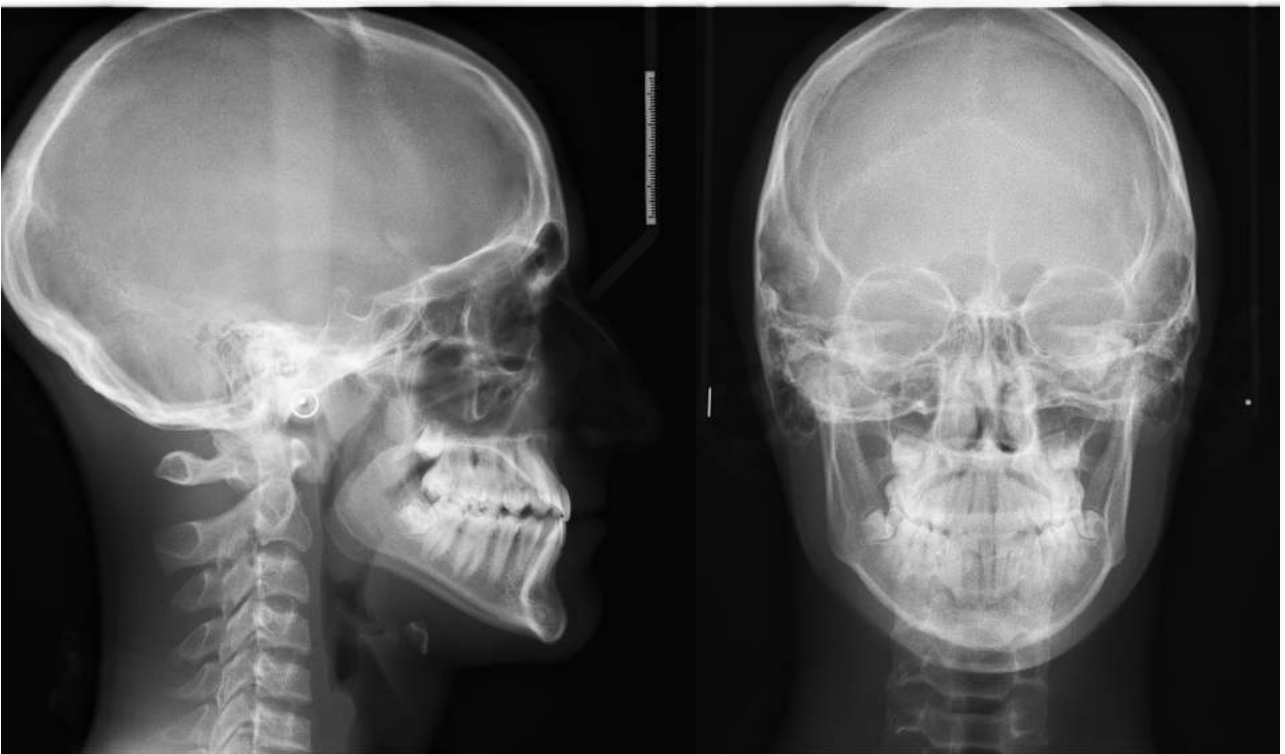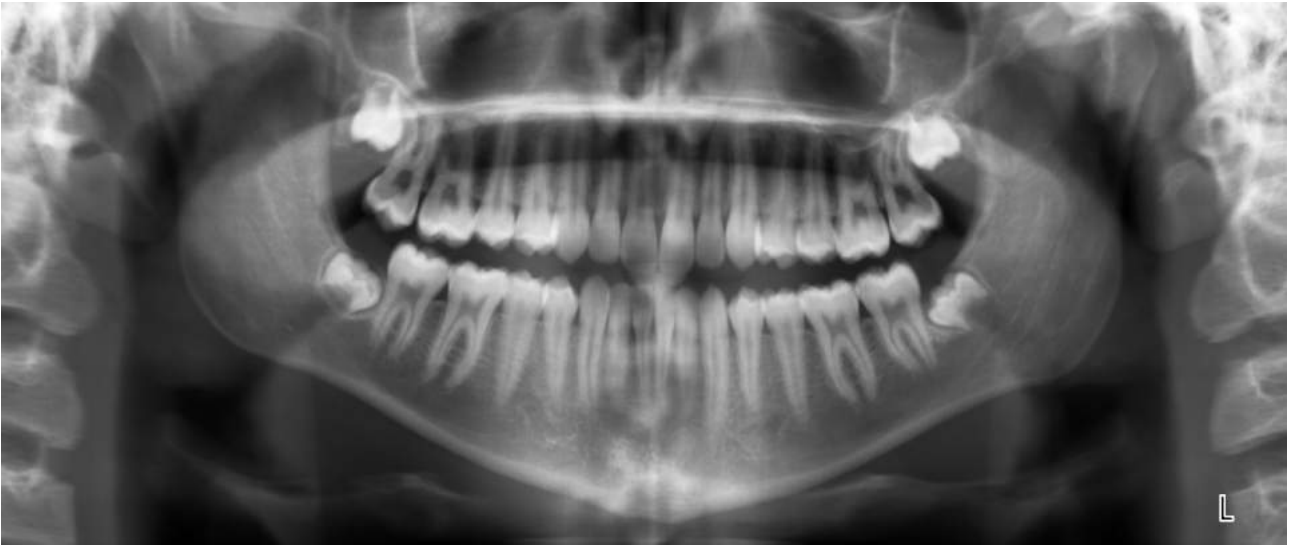S.B. 14 years of age



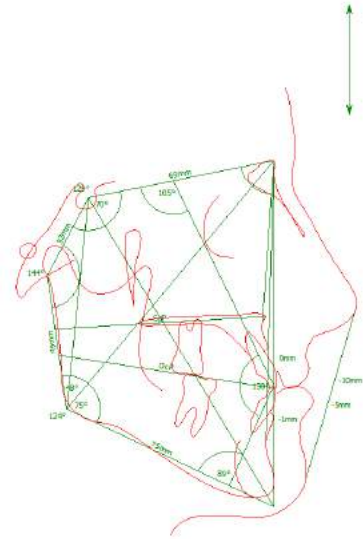
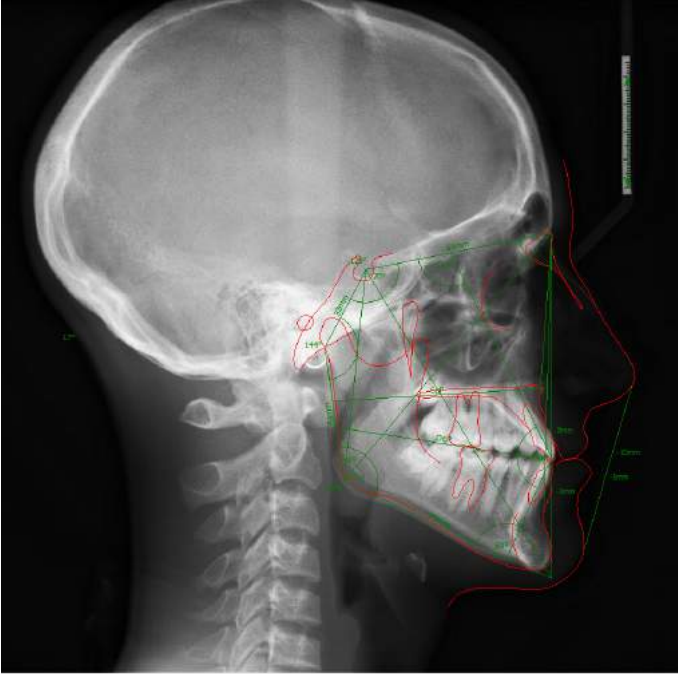


Initial intraoral pictures

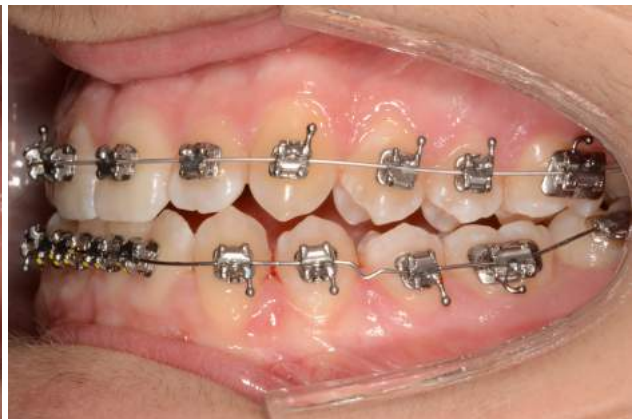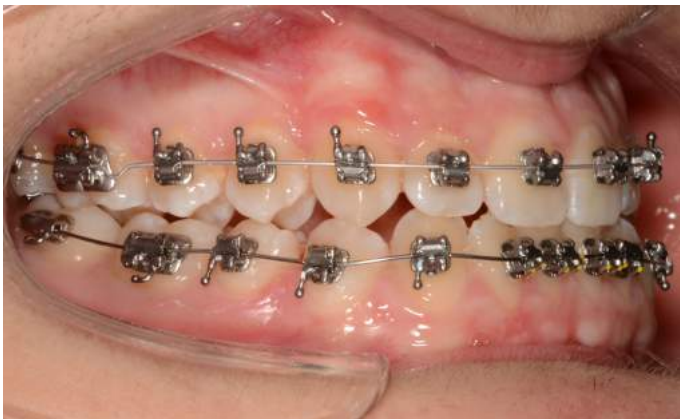


Initial xrays to evaluate the patient

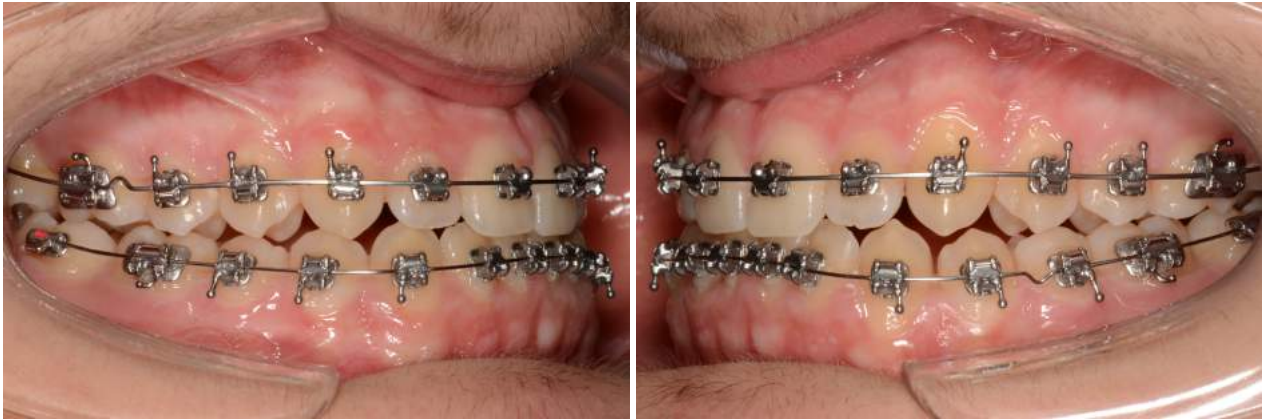




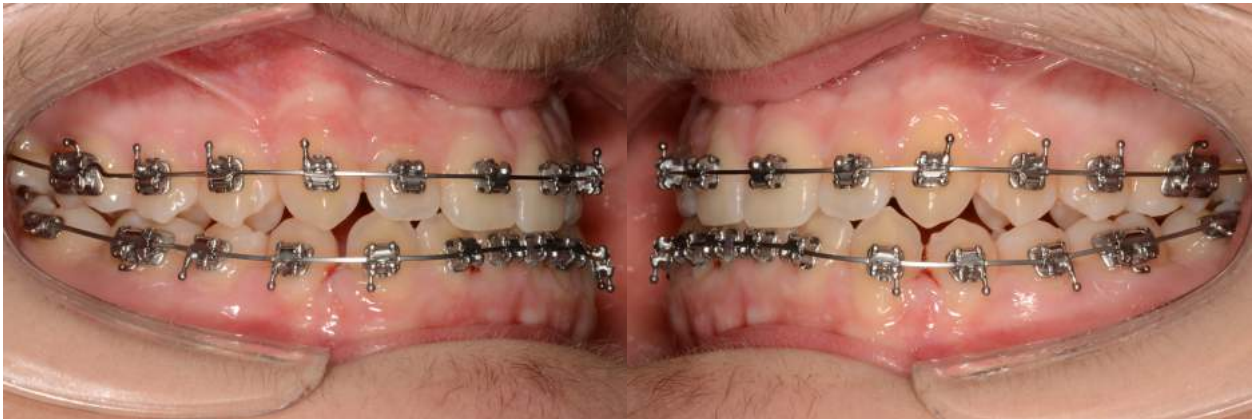
Tracing and cephalometric analysis



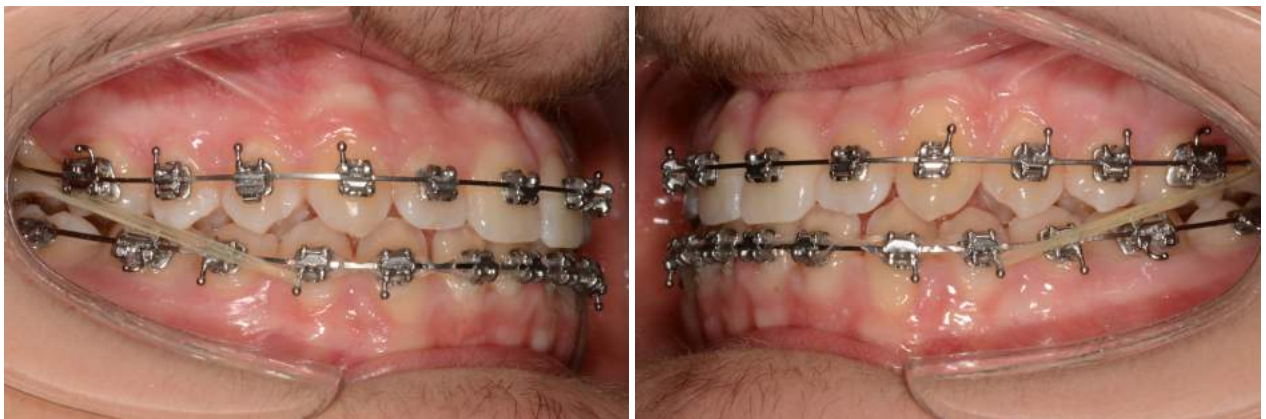First upper and lower .016" Sentalloy archwires



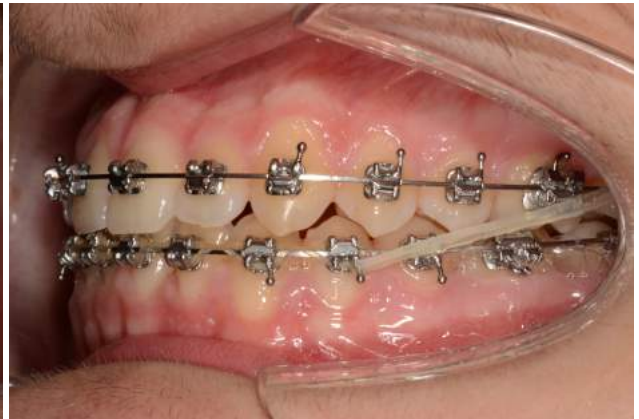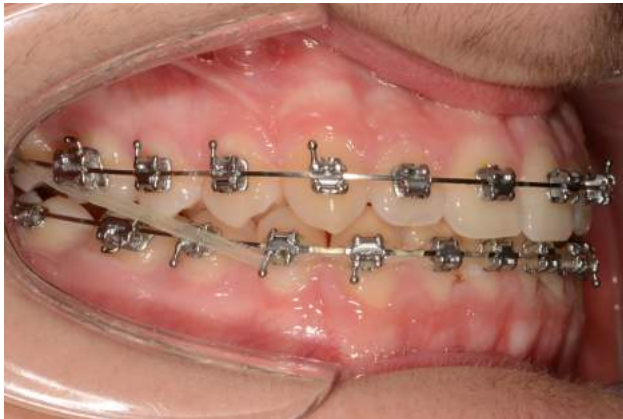
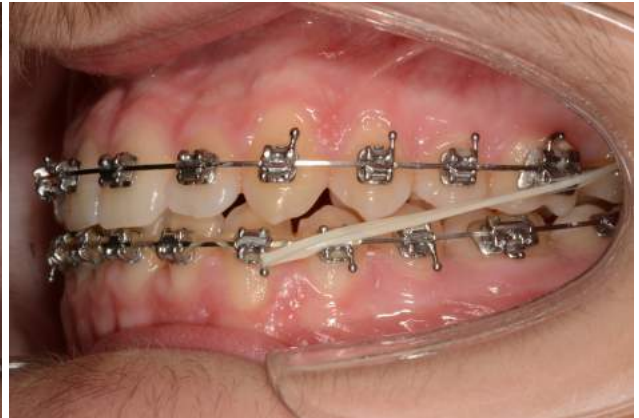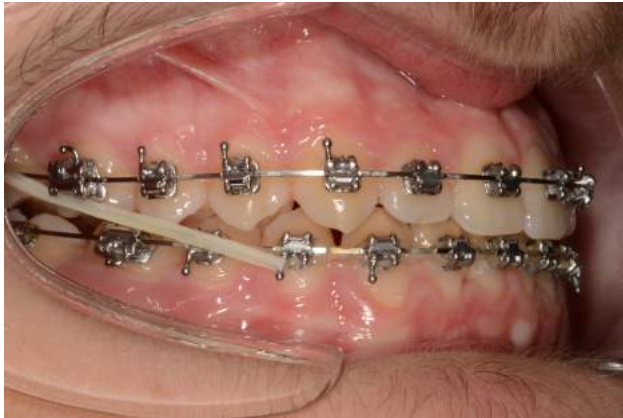Upper .020"x.020" Bioforce and lower .018 Sentalloy archwires



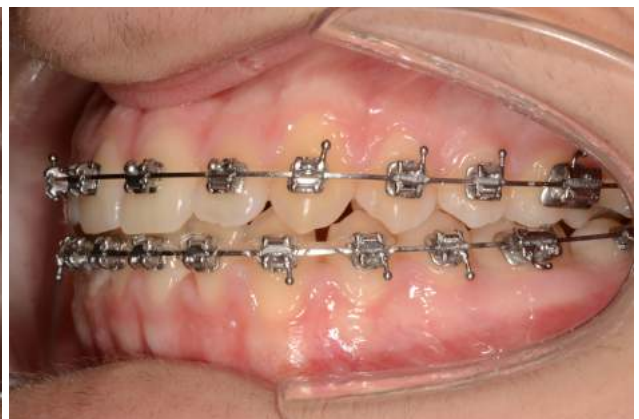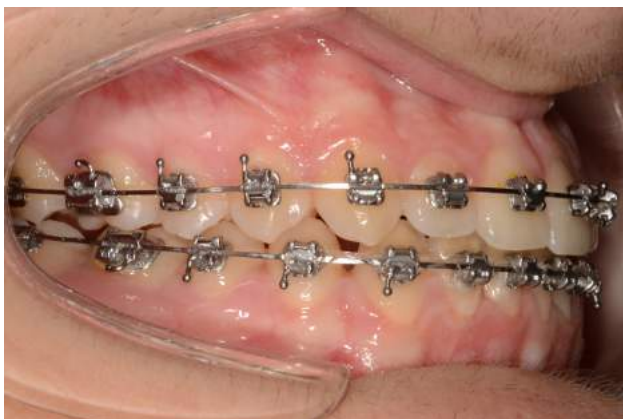
Upper and lower .020"x.020" Bioforce archwires



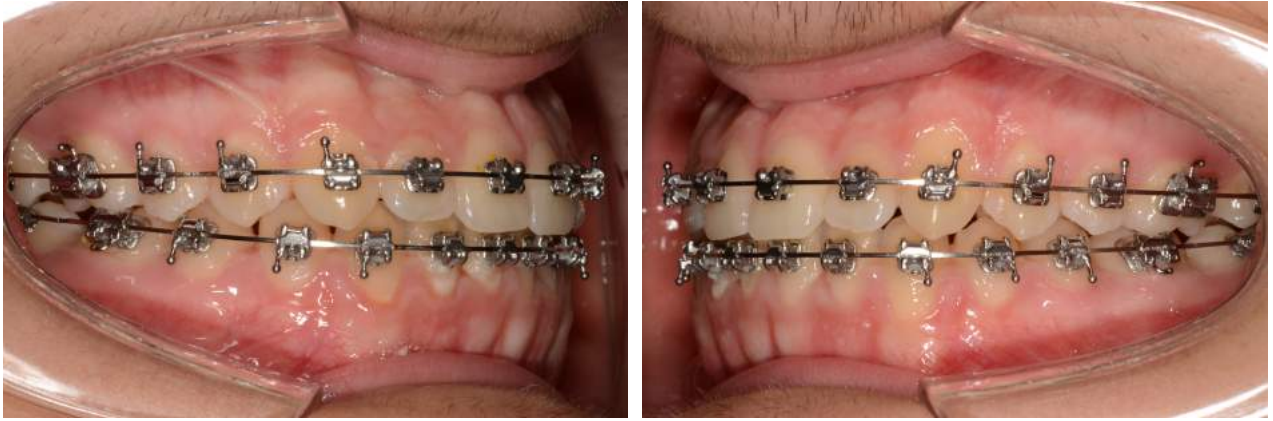




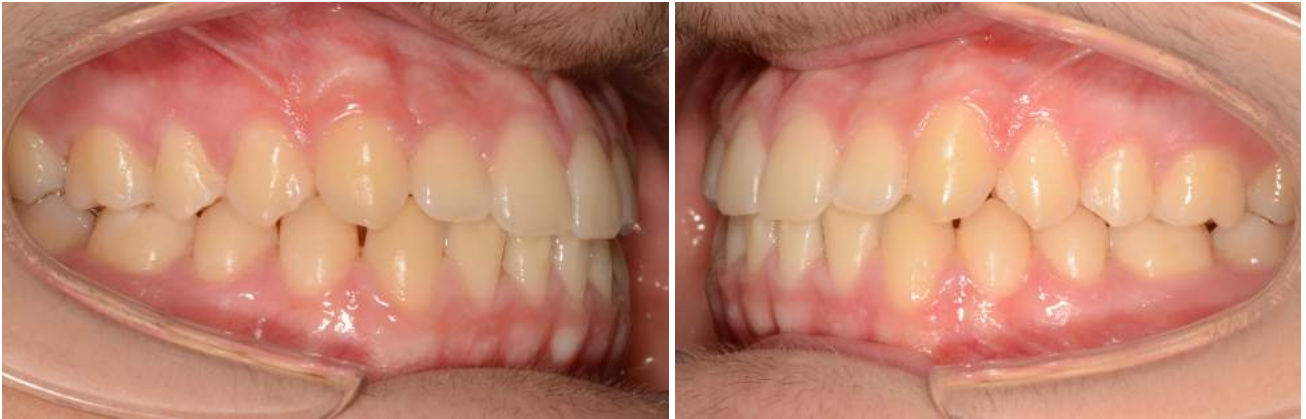Working stage with initial upper and lower .019"x.025" SS archwires and Class II elastics  
Lower archwire was then changed in a .021"x.025" SS archwire



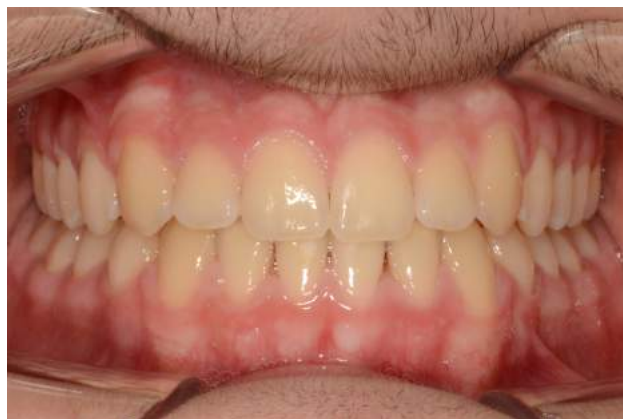Elastic chains to close residual spaces



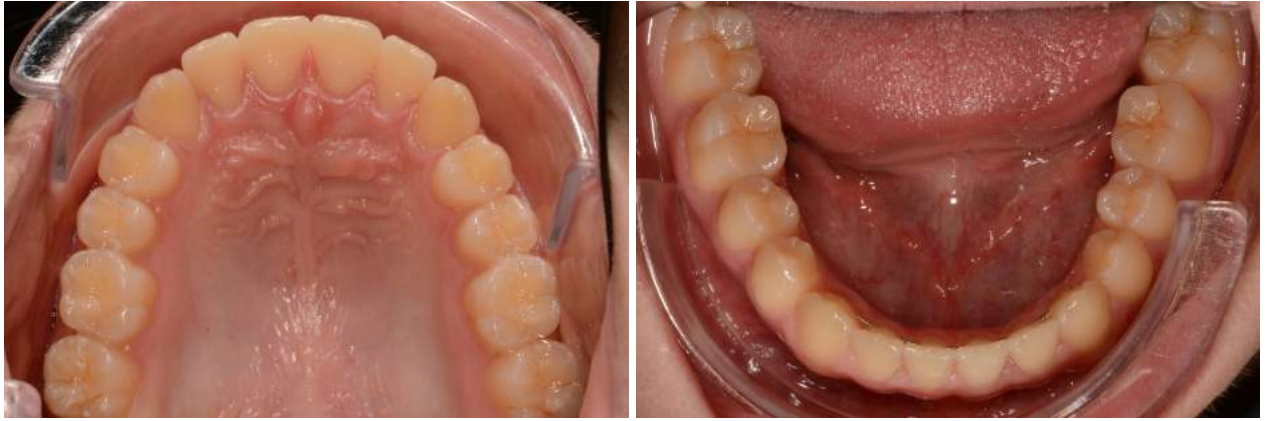Upper and lower 021"x.025" SS archwires



Final result after 17 months of treatment



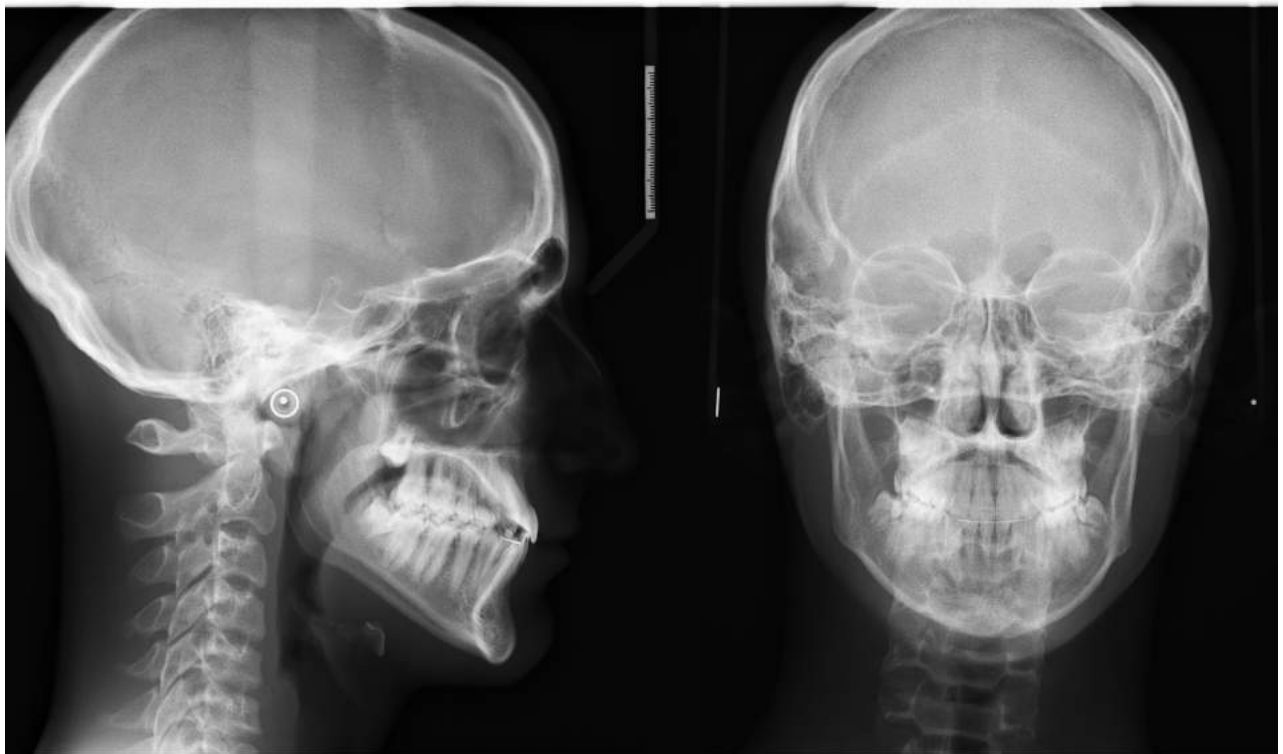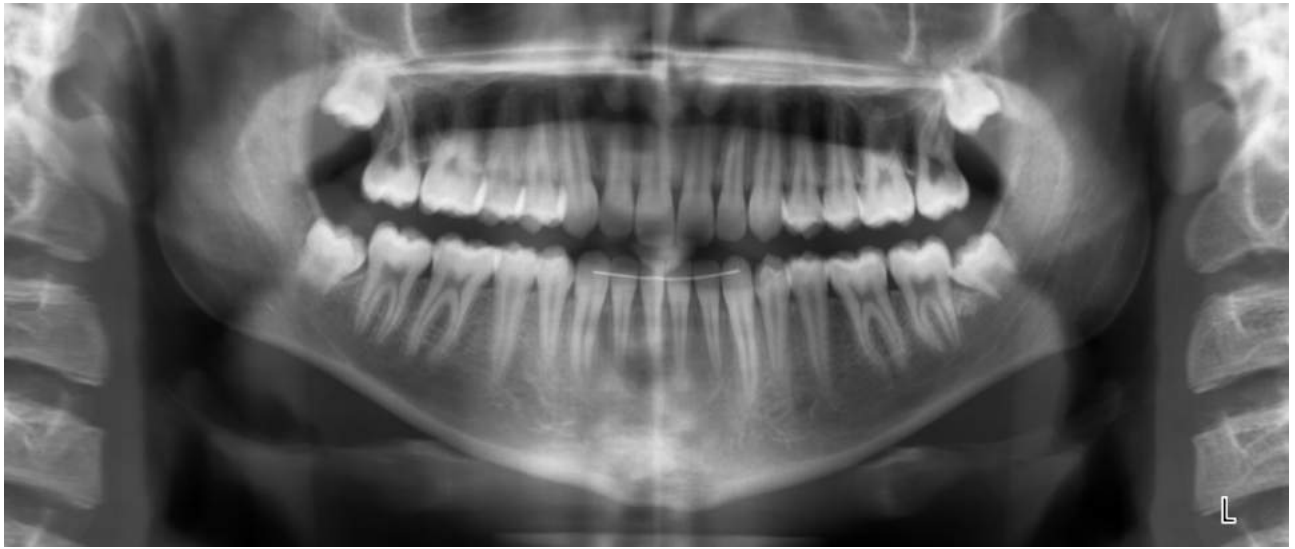




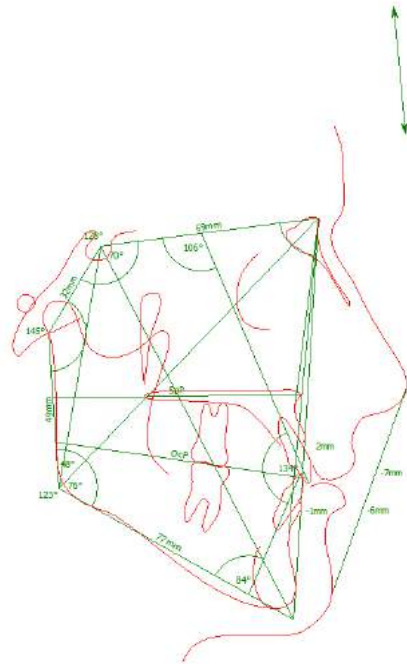
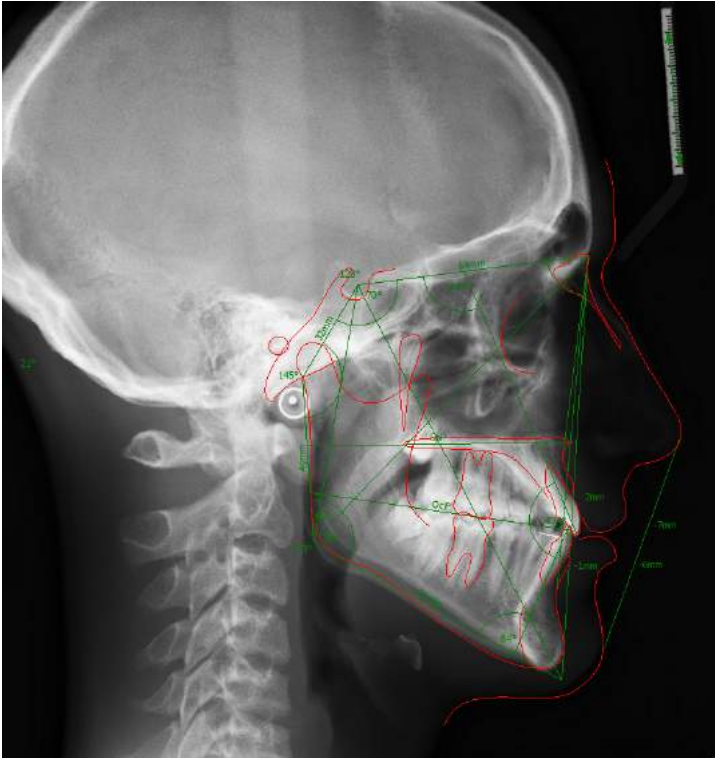
Final result after 17 months of treatment



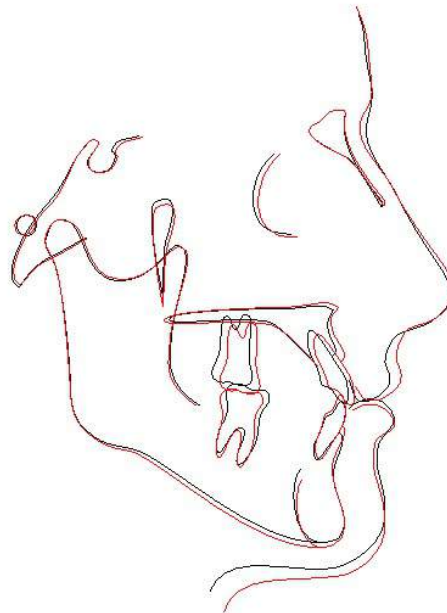




Final xrays



### Tracing and cephalometric analysis



### General Superimposition