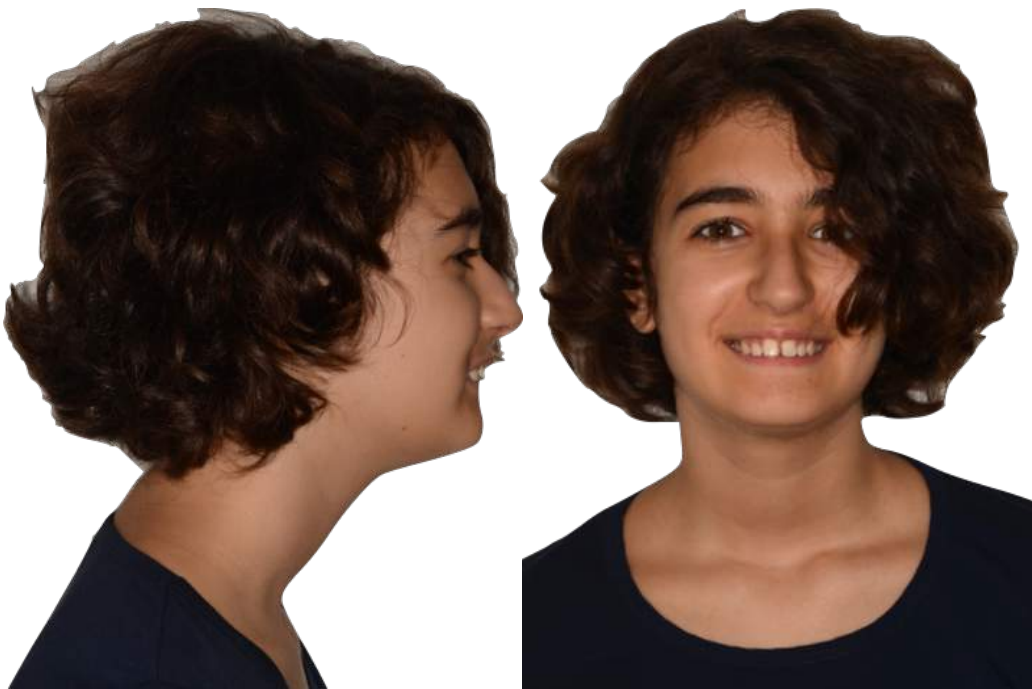
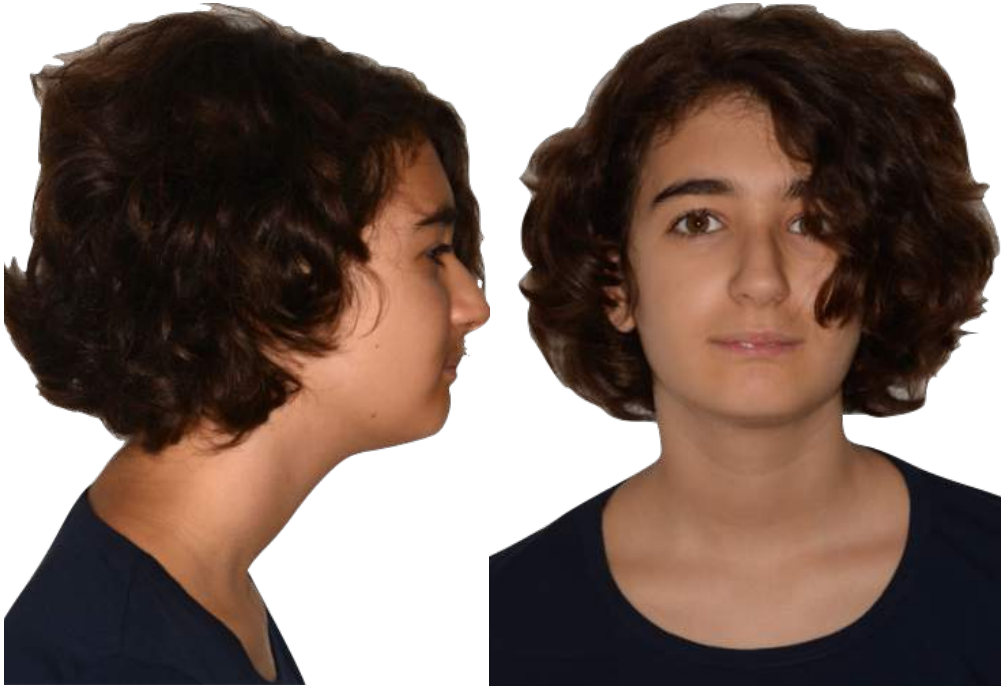
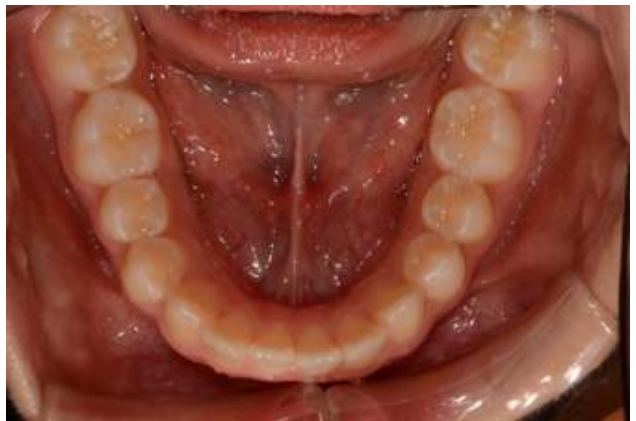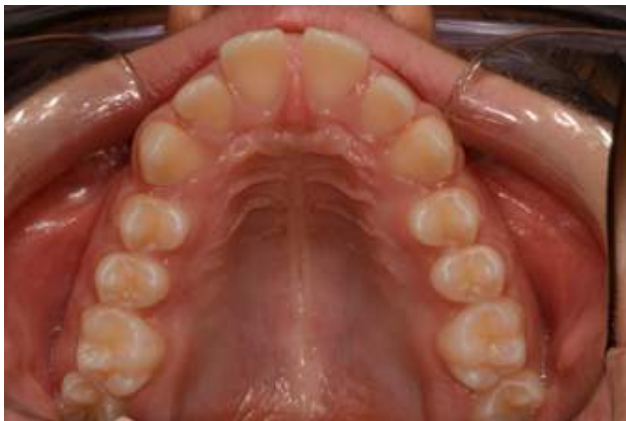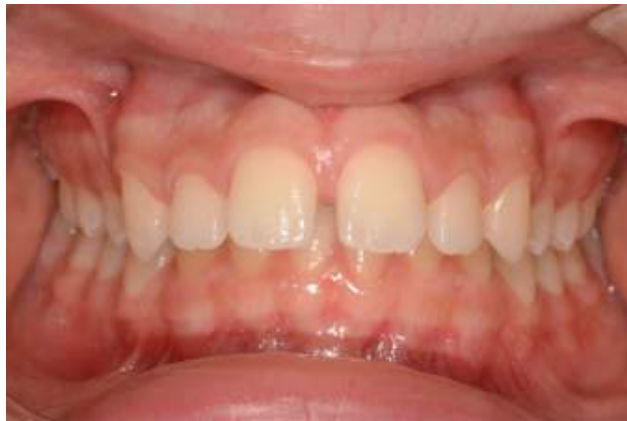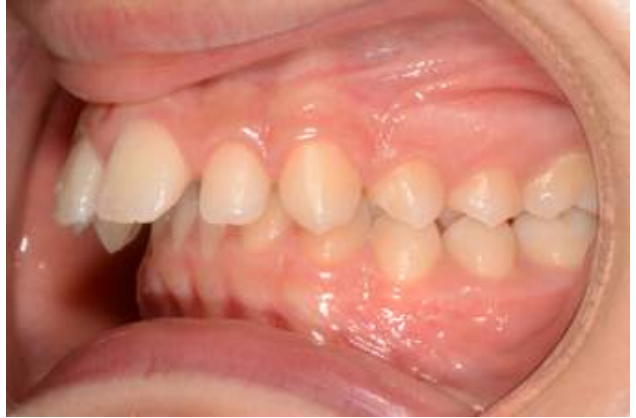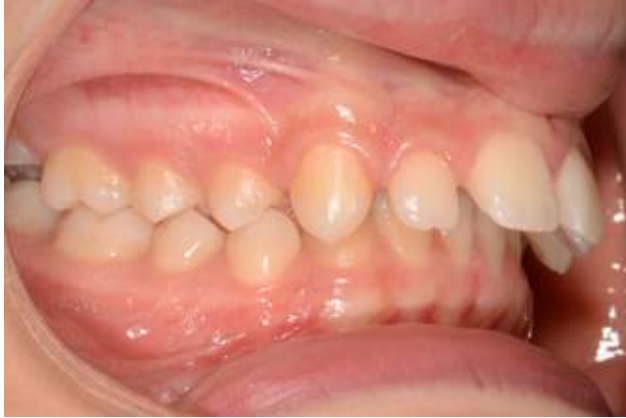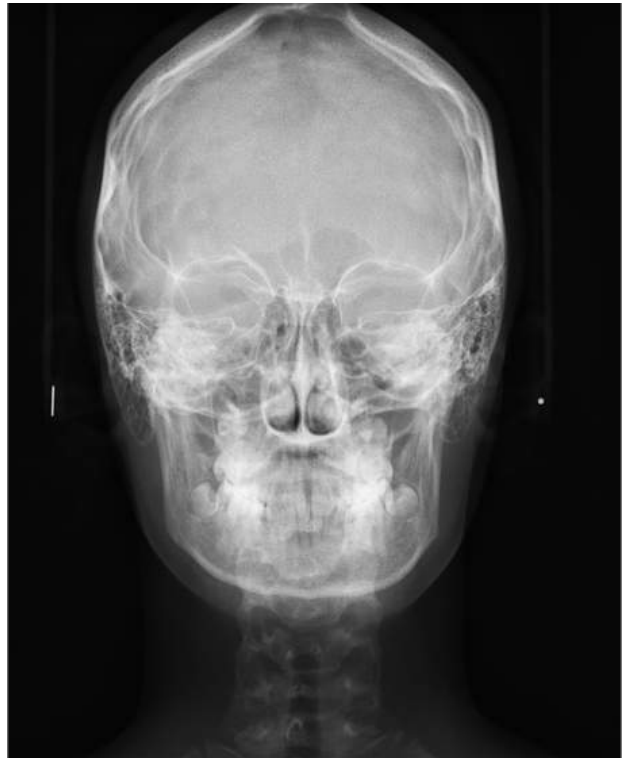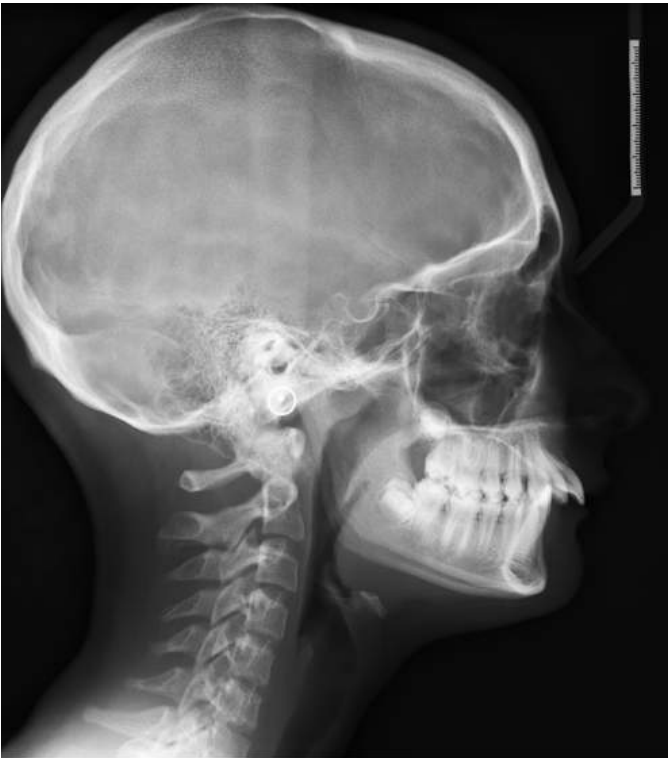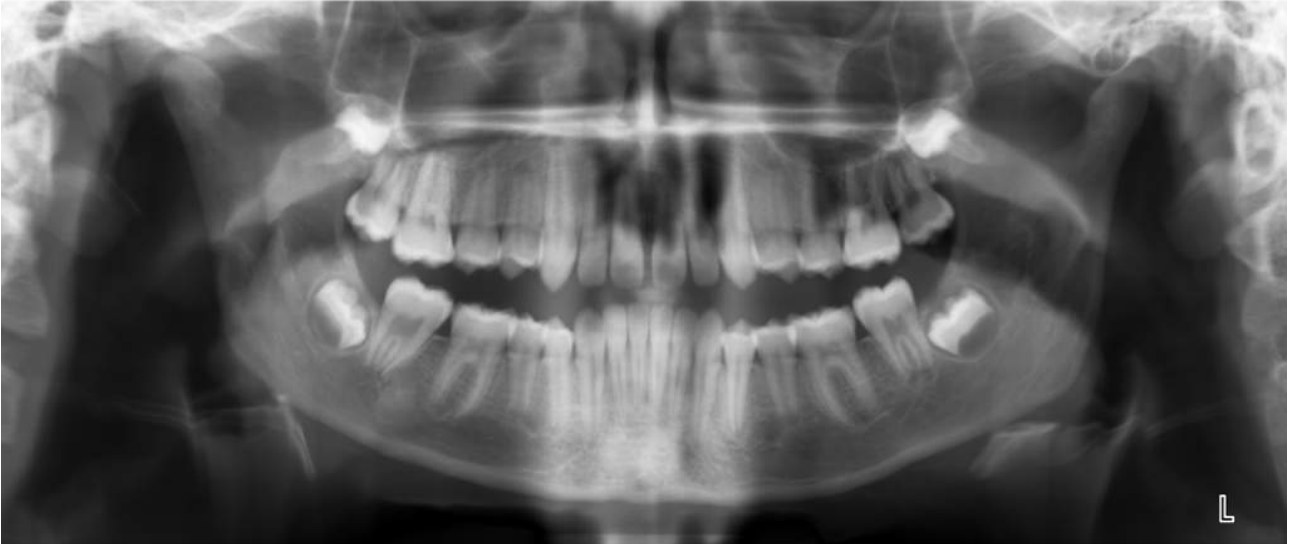I.C. 12 years of age  
Thumb and lower lip sucker

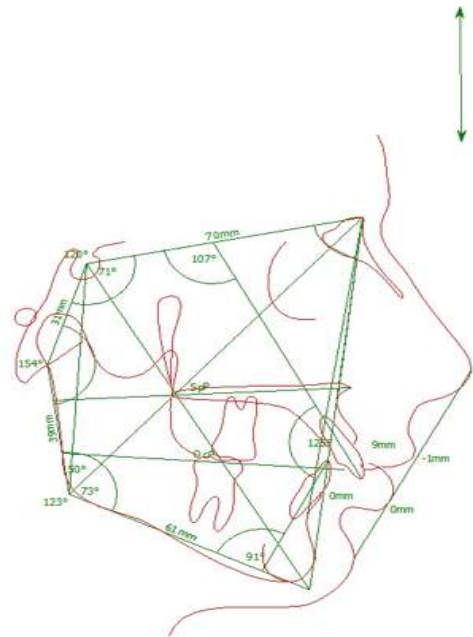
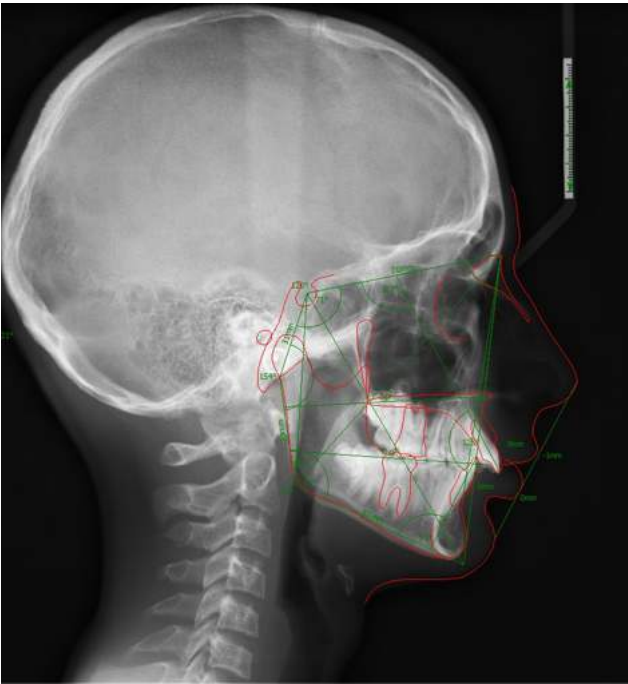




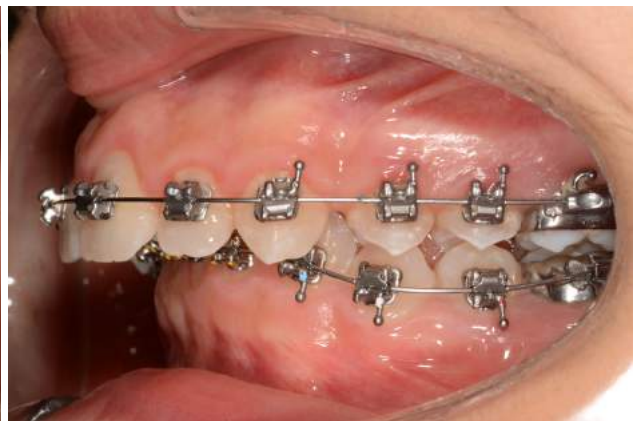
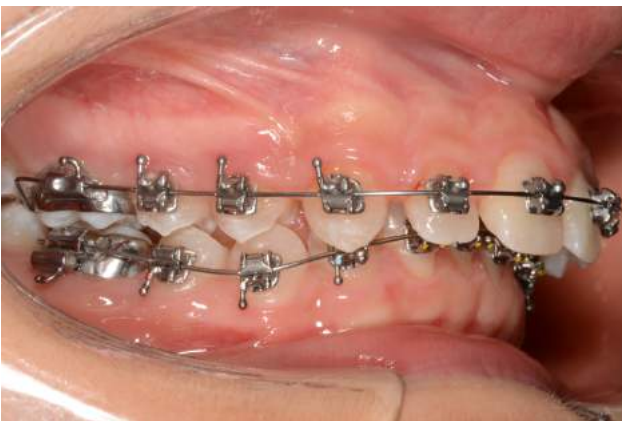
Initial intraoral pictures



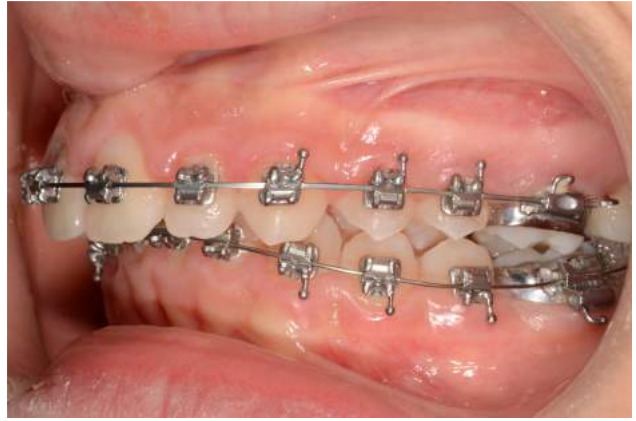
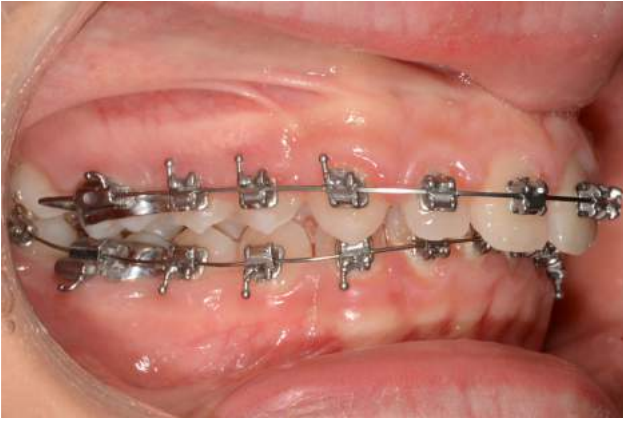
Initial xrays



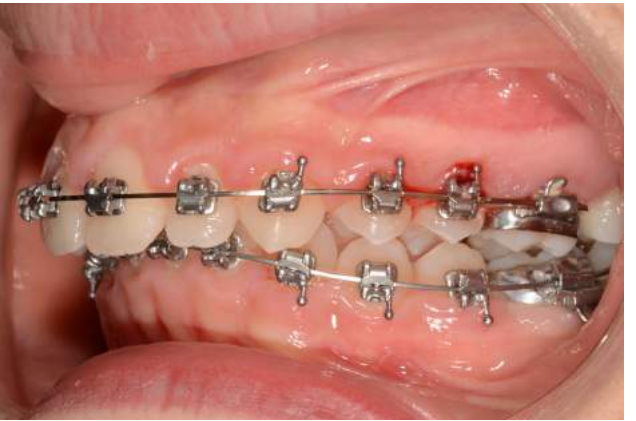
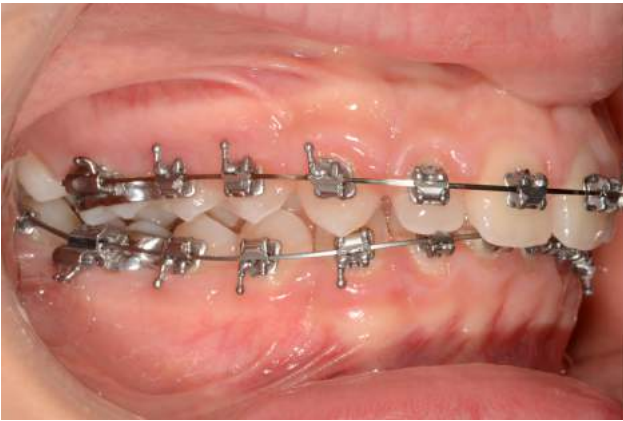
Tracing and cephalometric analysis



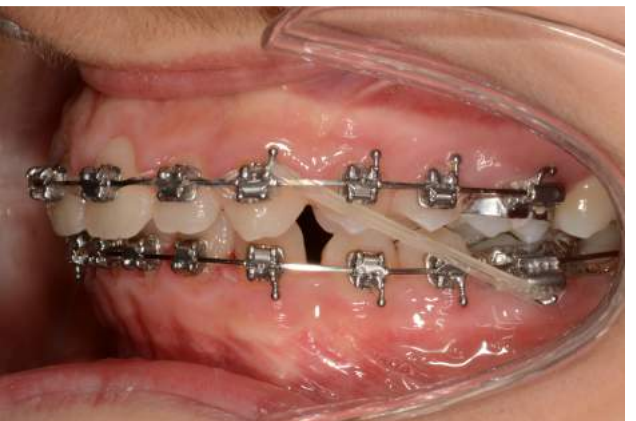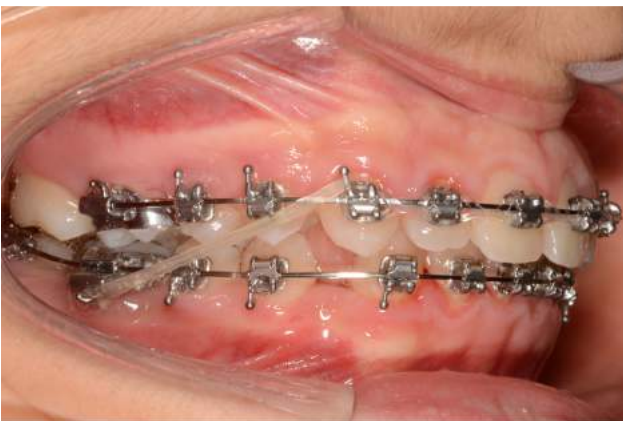First upper and lower .016" Sentalloy archwires

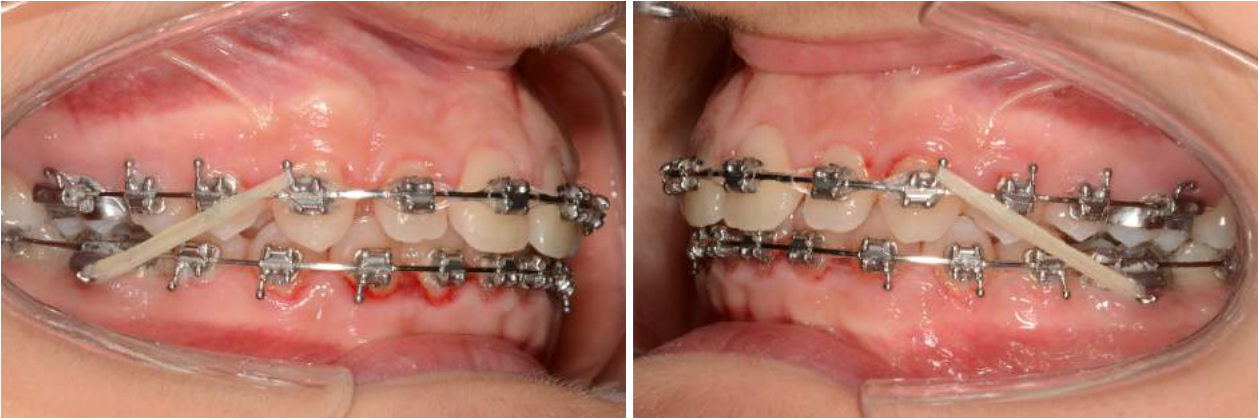

Upper .020"x.020" Bioforce and lower .018 Sentalloy archwires

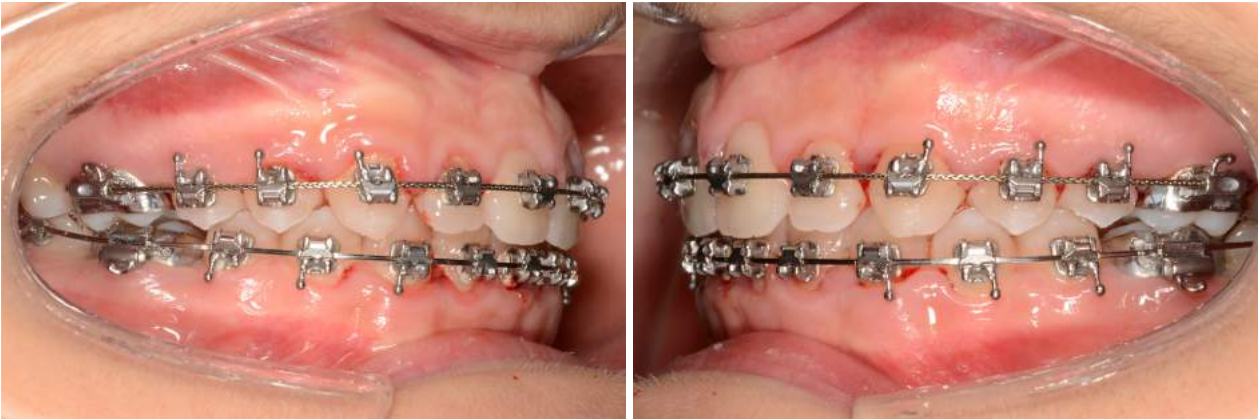

Upper .019x.025 SS and lower .020"x.020" Bioforce archwires

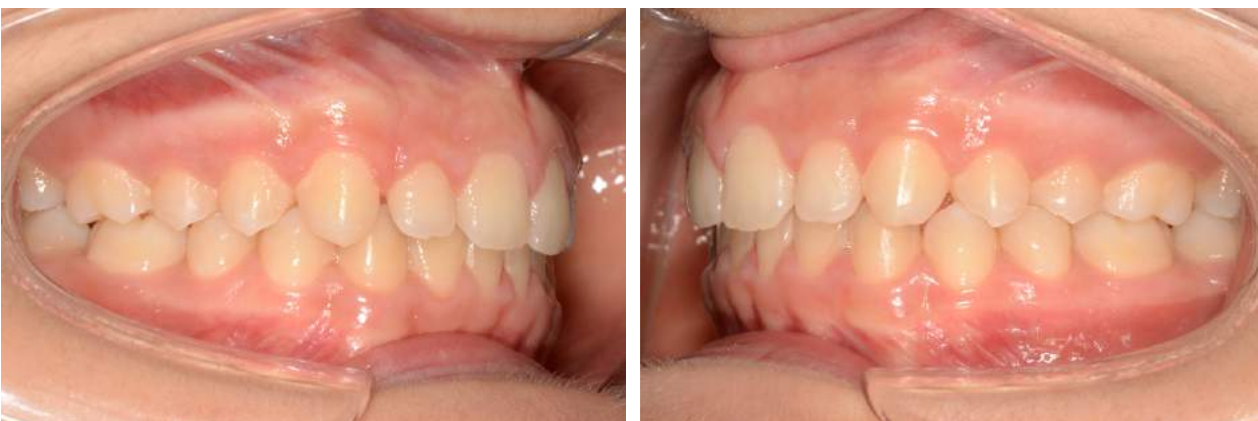



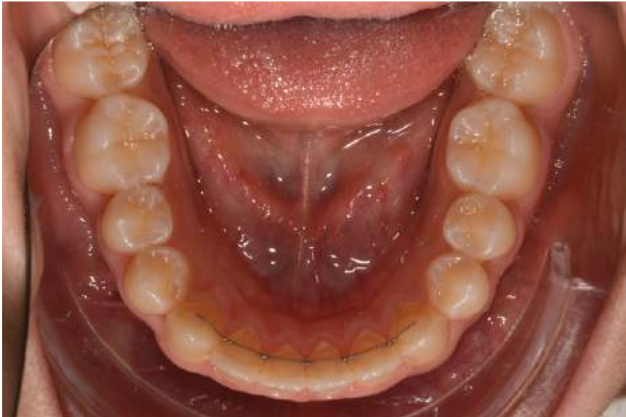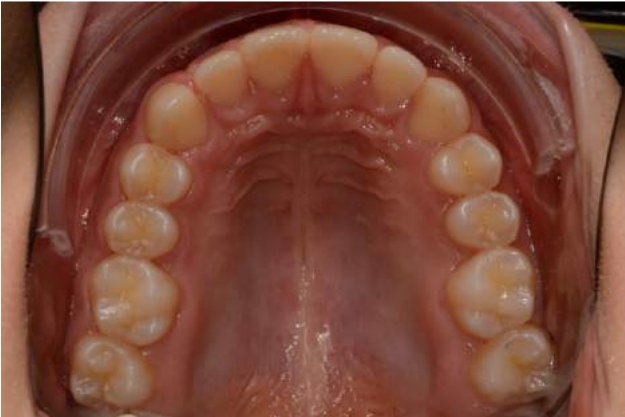
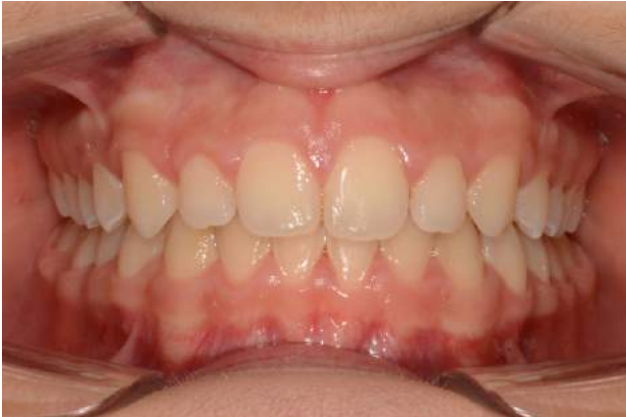Working stage with initial upper and lower .019"x.025" SS archwires and Class II elastics  
Lower archwire was then changed in a .021"x.025" SS archwire



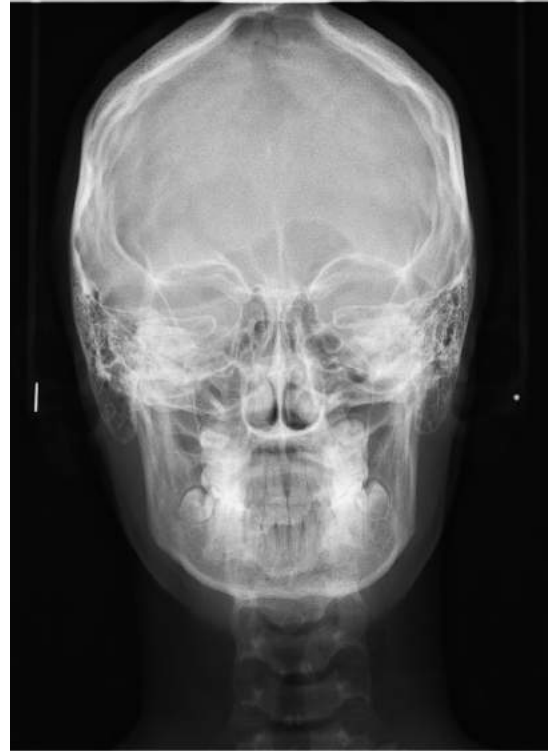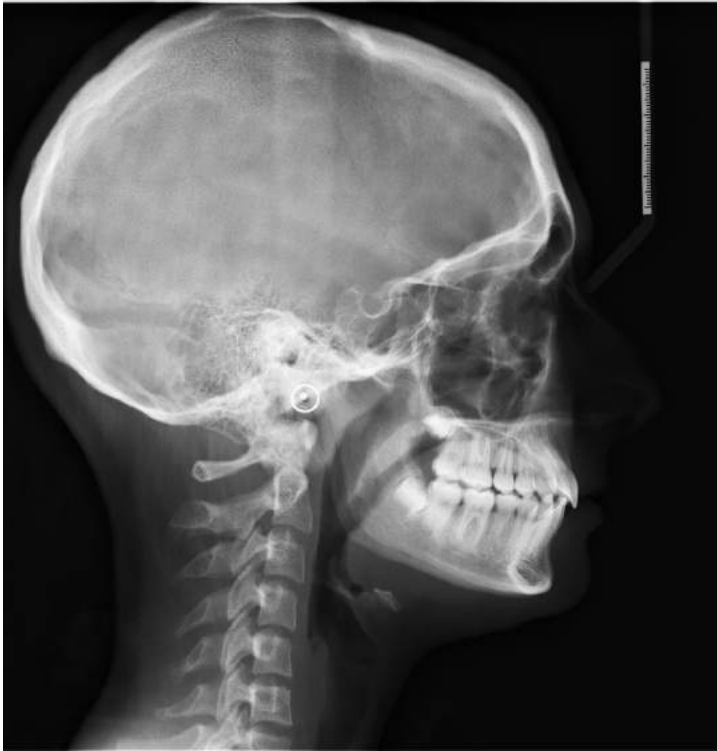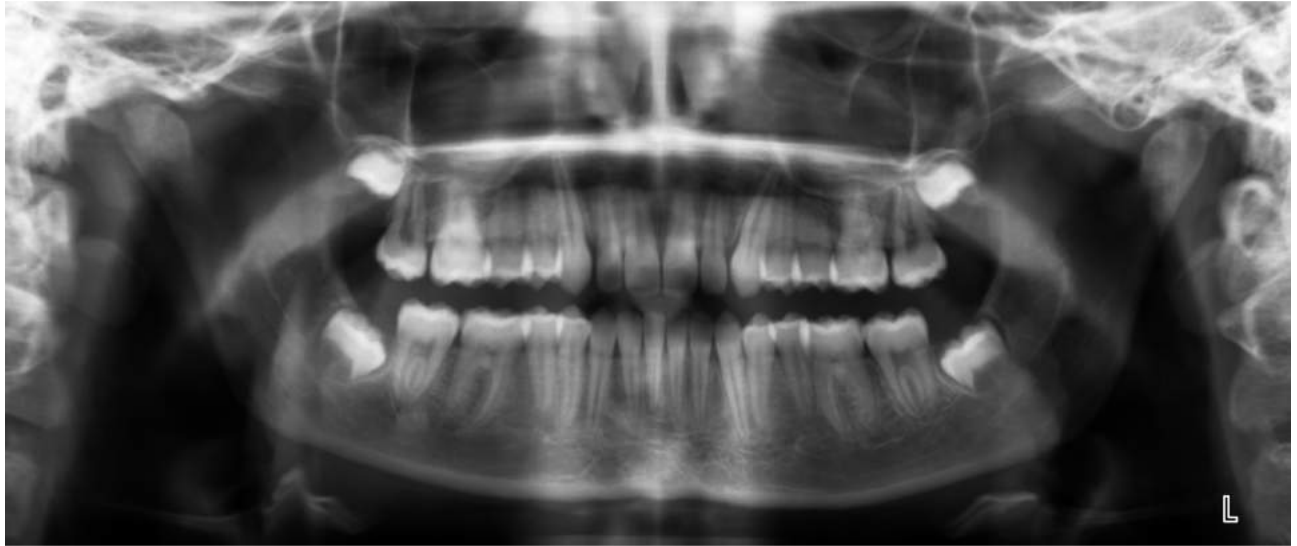After some minor rebonding,  
detailing with upper .021"x.025" MB archwire and lower .021"x.025" SS archwire  
and triangular vertical elastics



Final result after 19 months of treatment

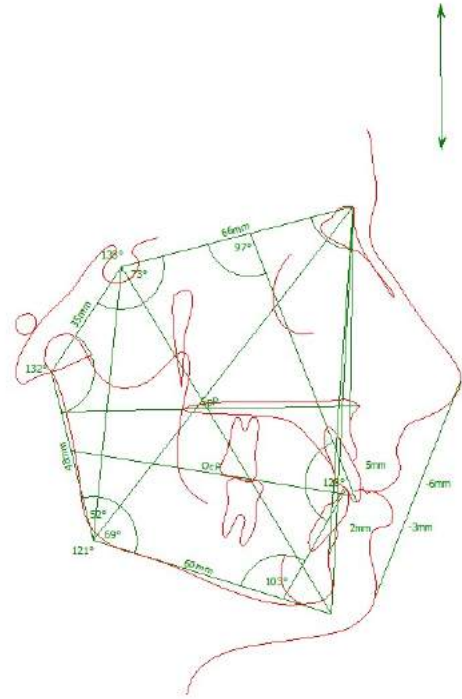
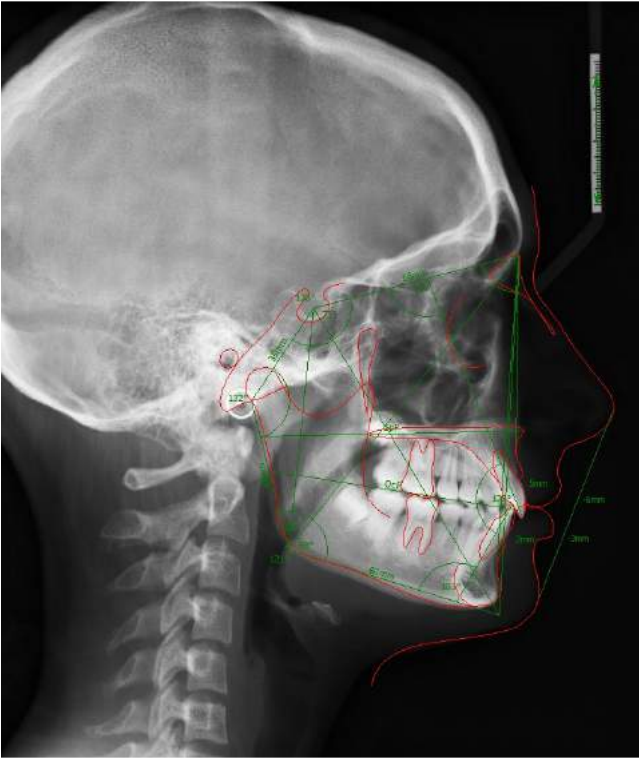


Final result after 19 months of treatment

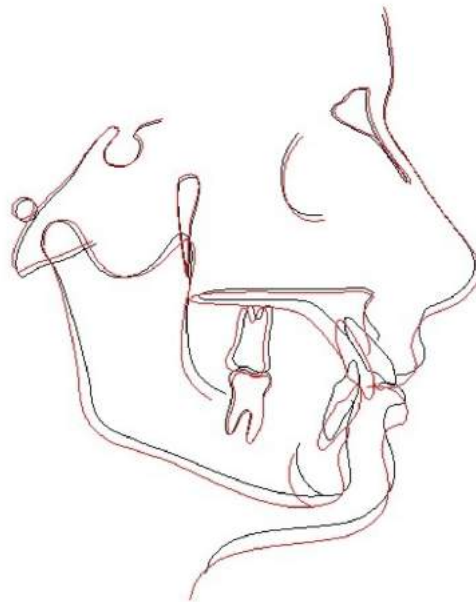


Final xrays





Tracing and cephalometric analysis



General Superimposition