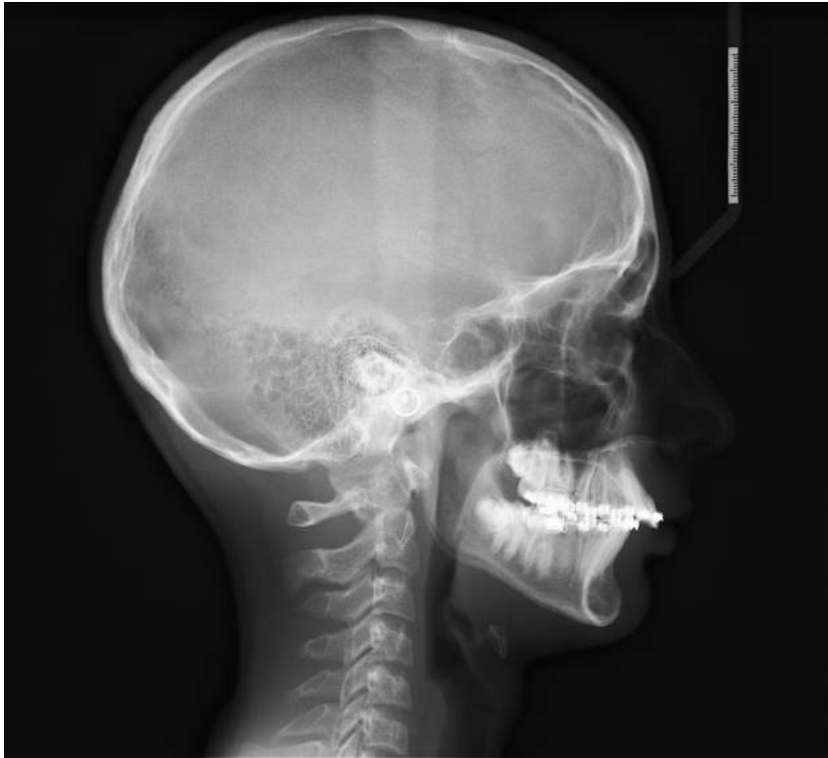
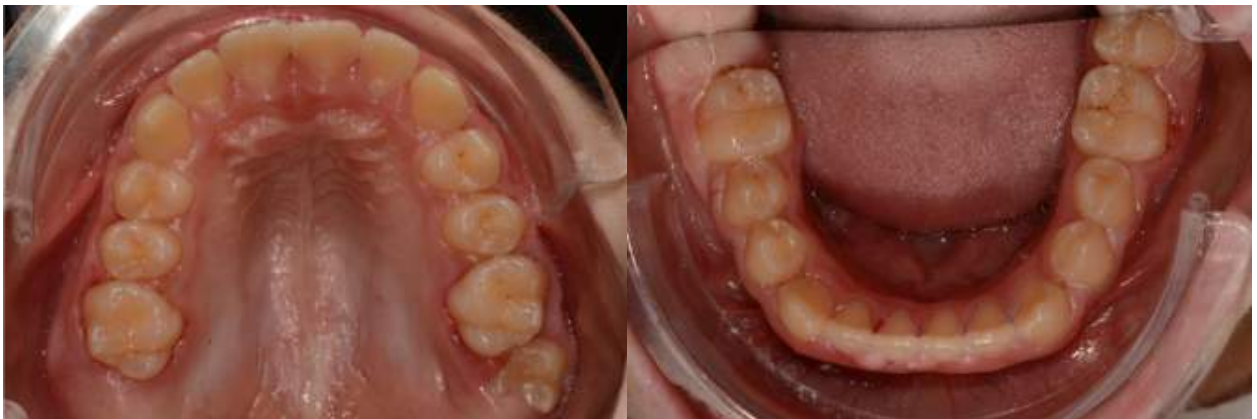
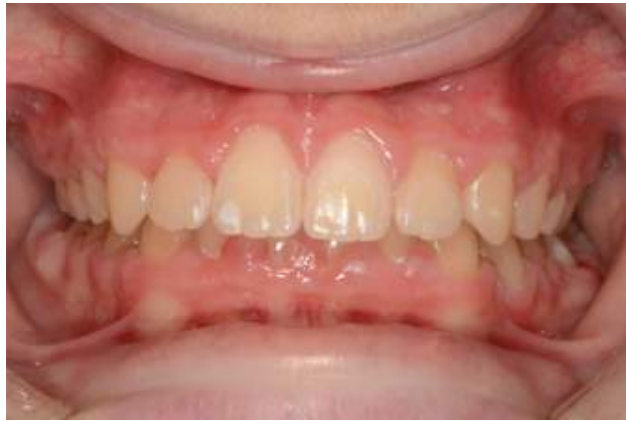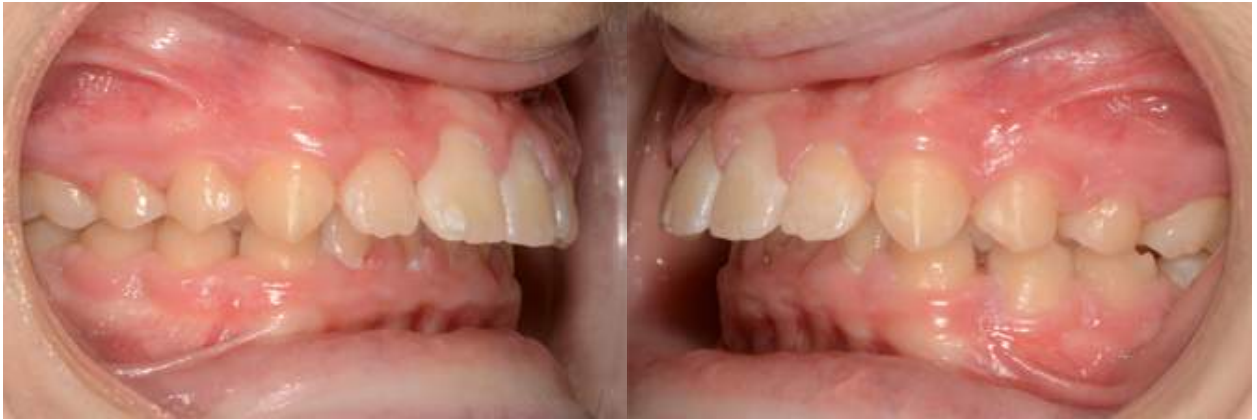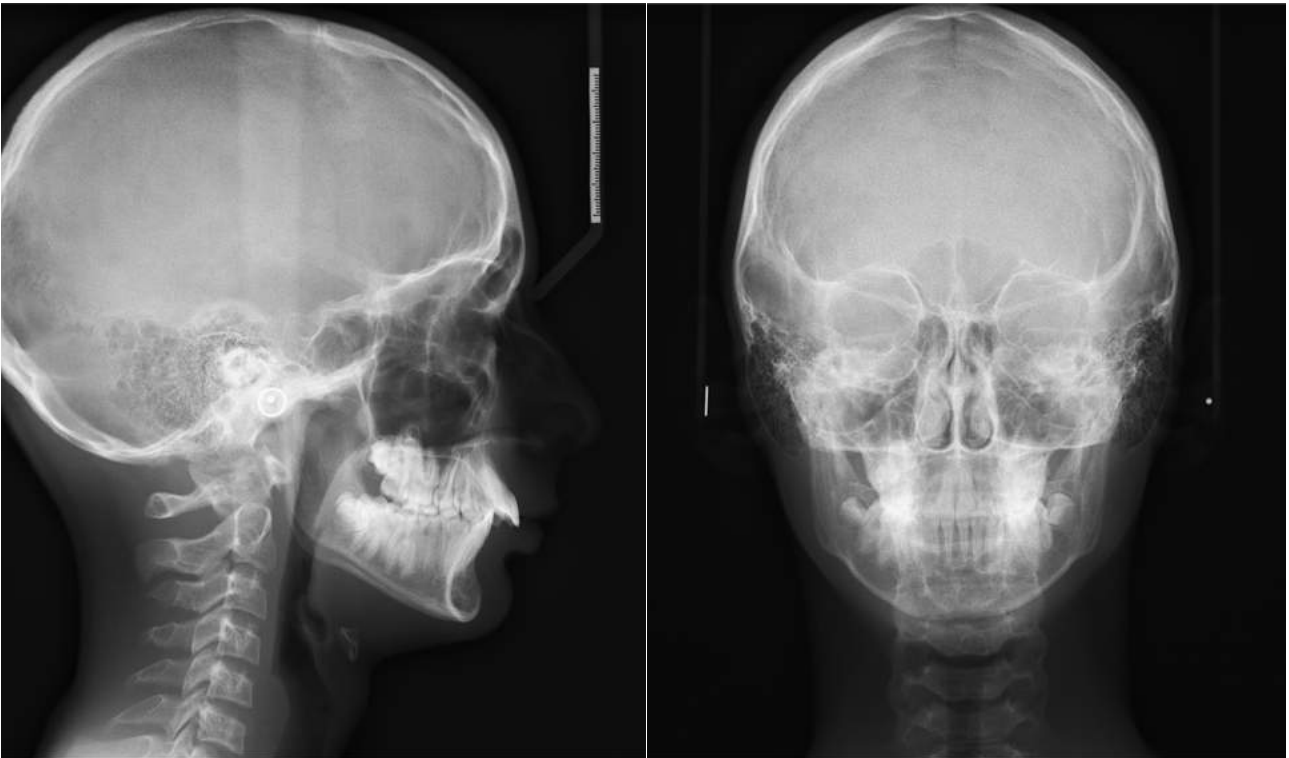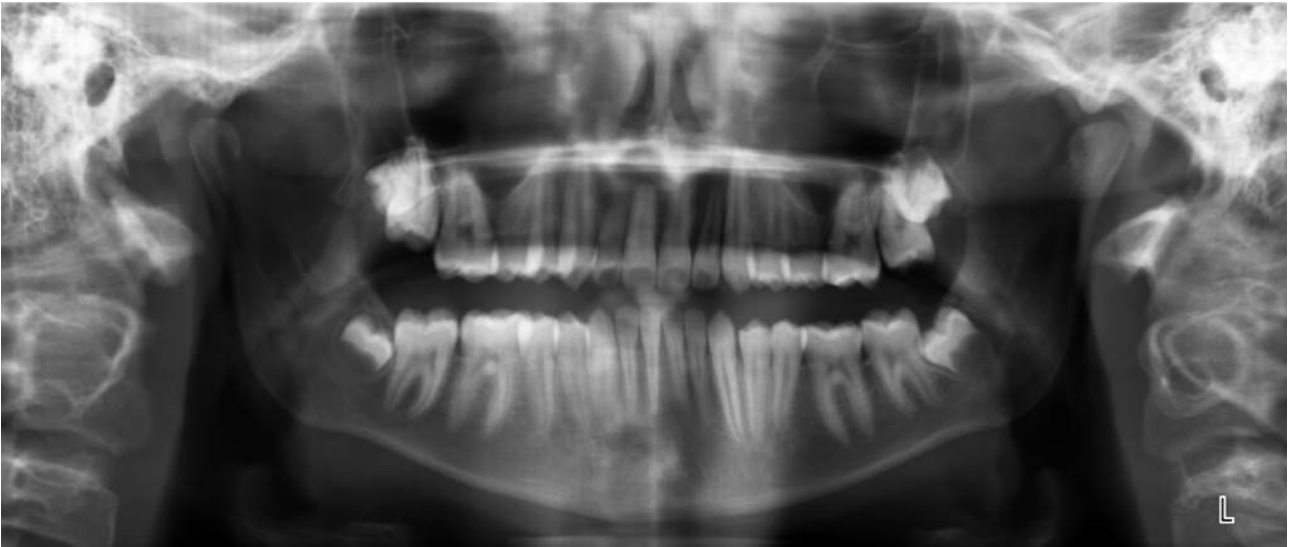A.F. 13 years of age
In treatment for 6 years without any result

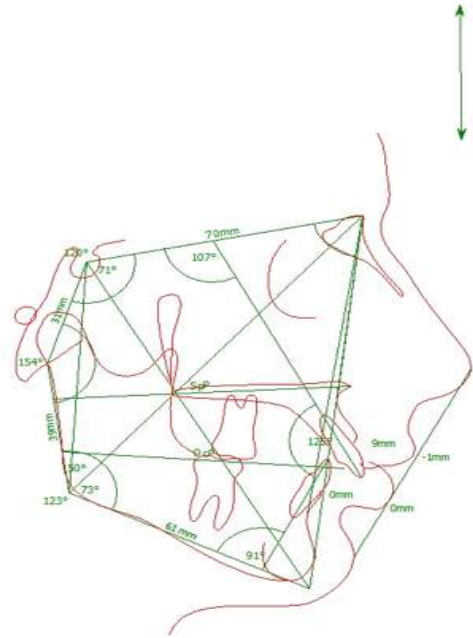
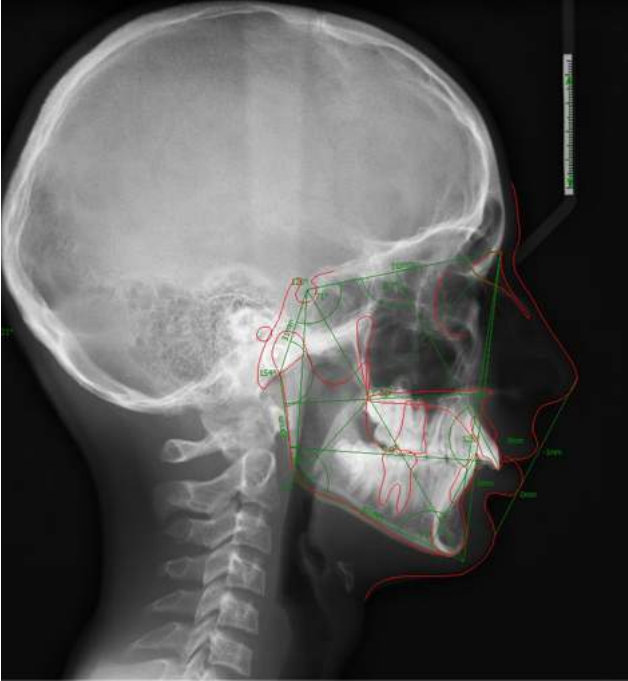




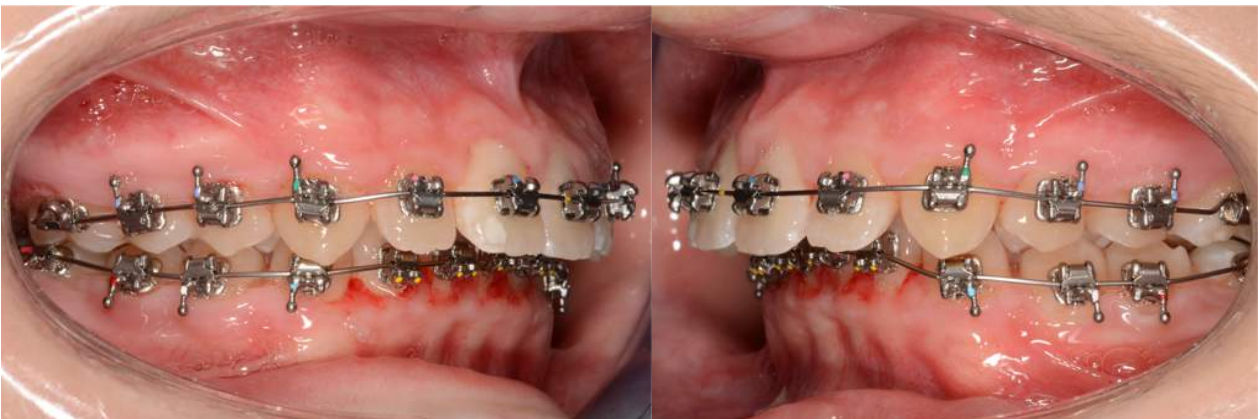After debonding and dental hygiene



Initial xrays to re-evaluate the patient

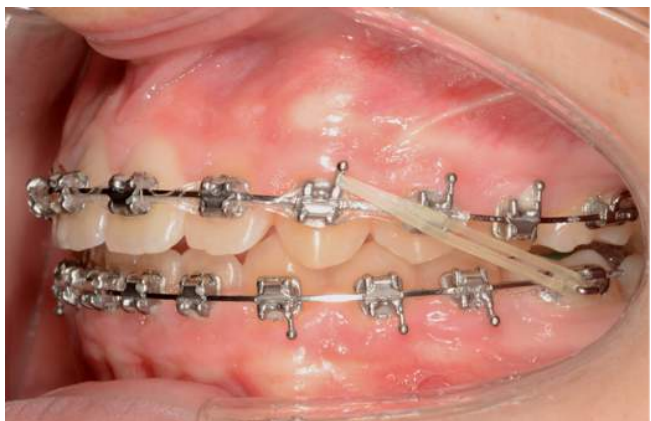
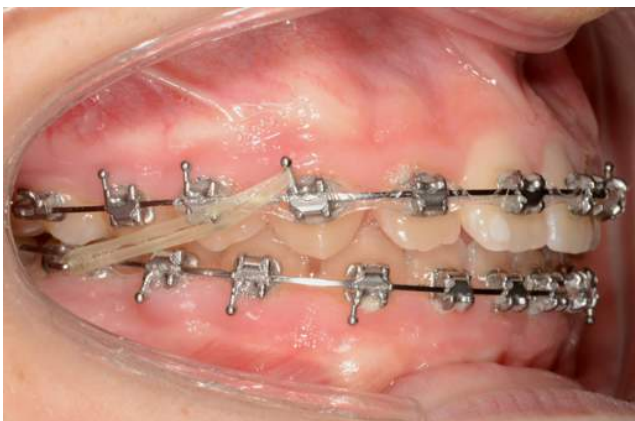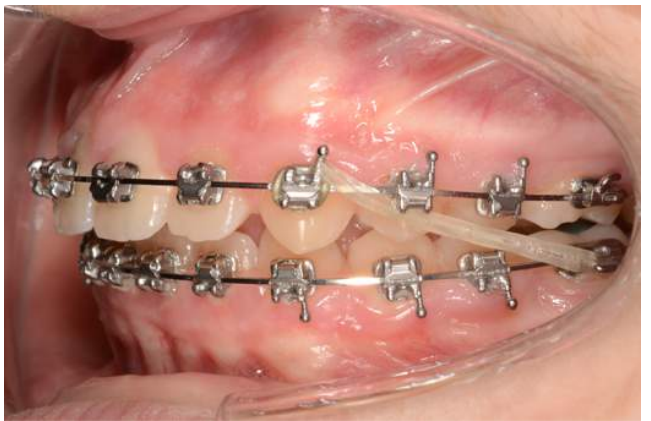
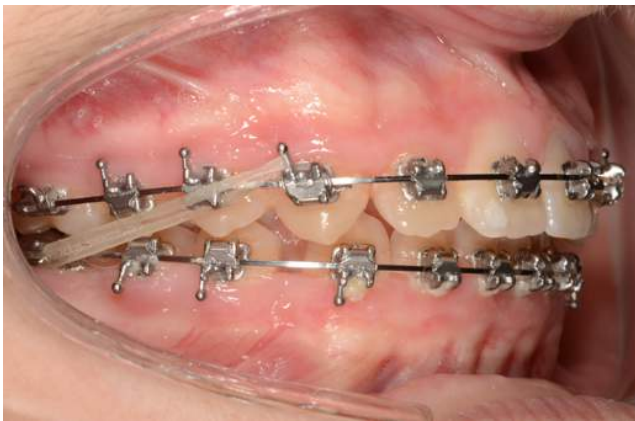
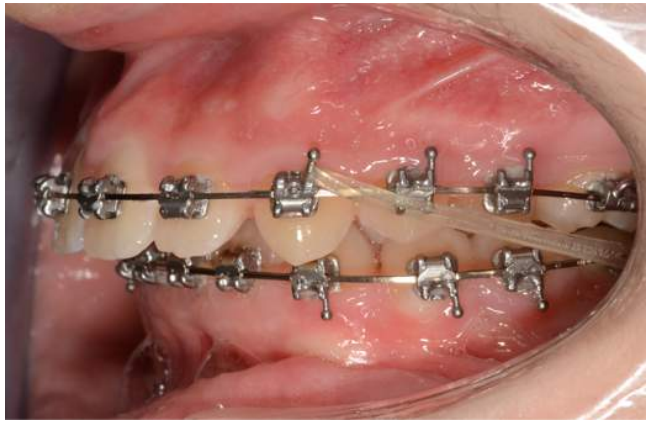
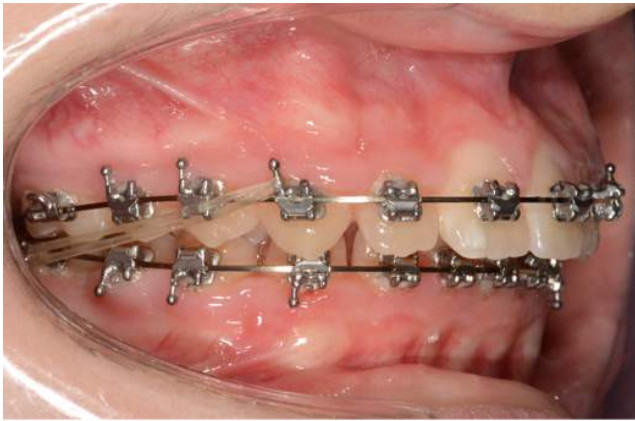


Tracing and cephalometric analysis

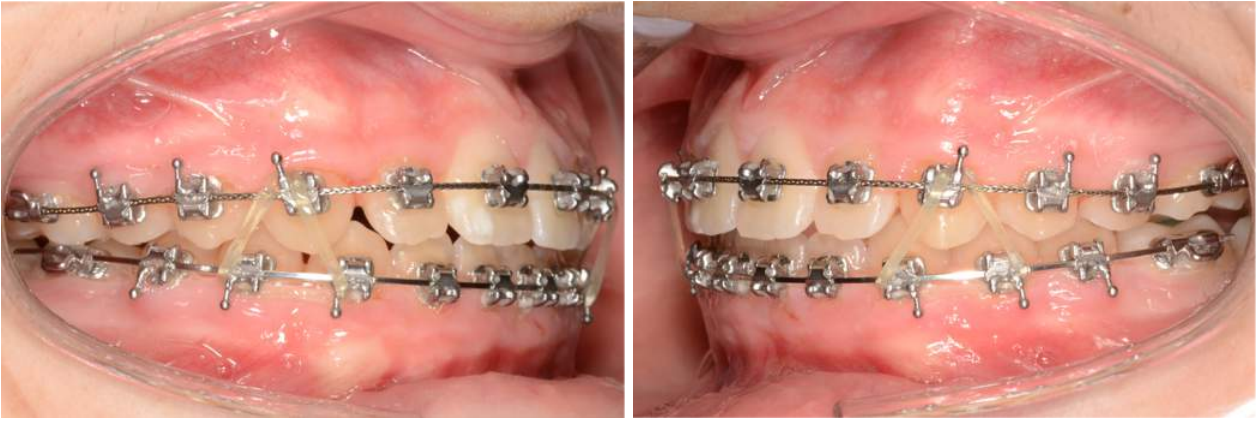


First upper and lower .016" Sentalloy archwires

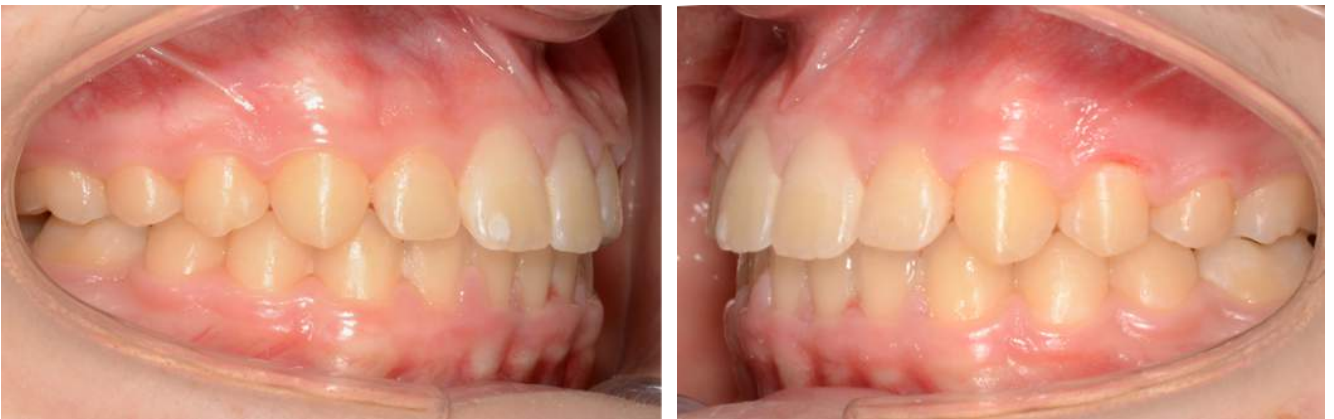These will be followed by .020"x.020" Bioforce archwires



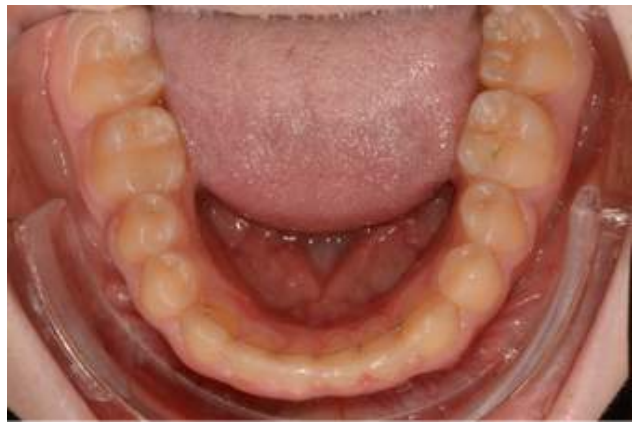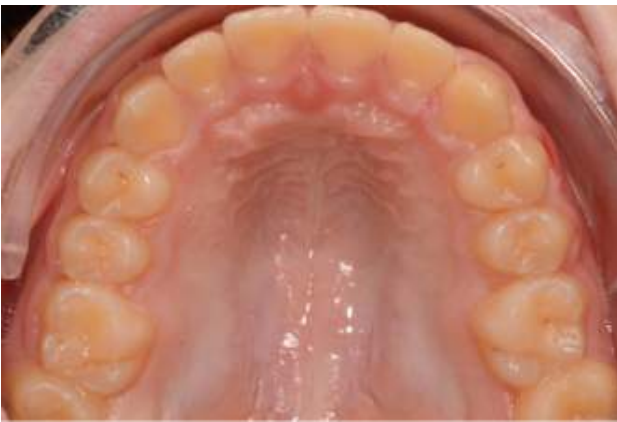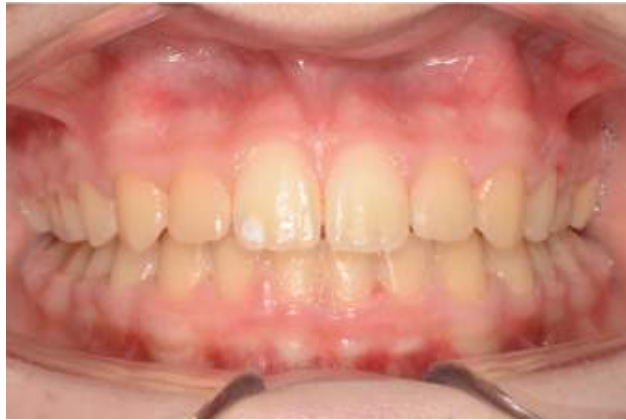Working stage with initial upper and lower .019"x.025" SS archwires and Class II elastics
Lower archwire was then changed in a .021"x.025" SS archwire



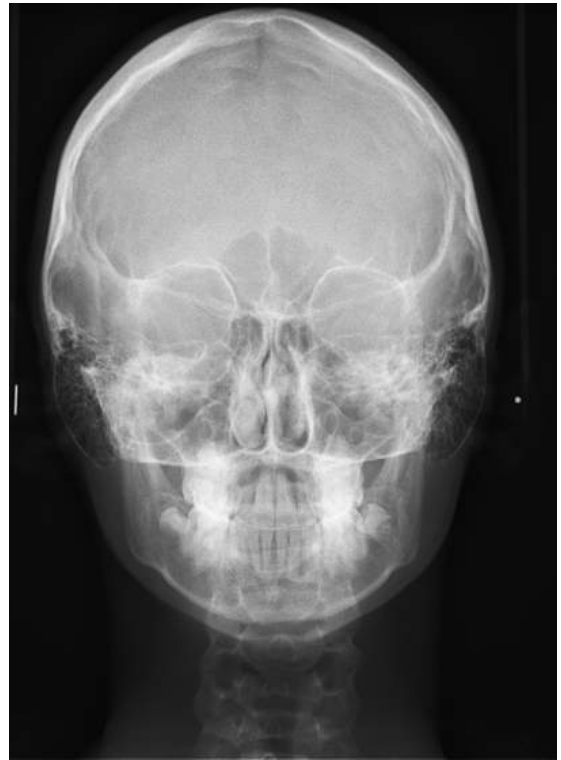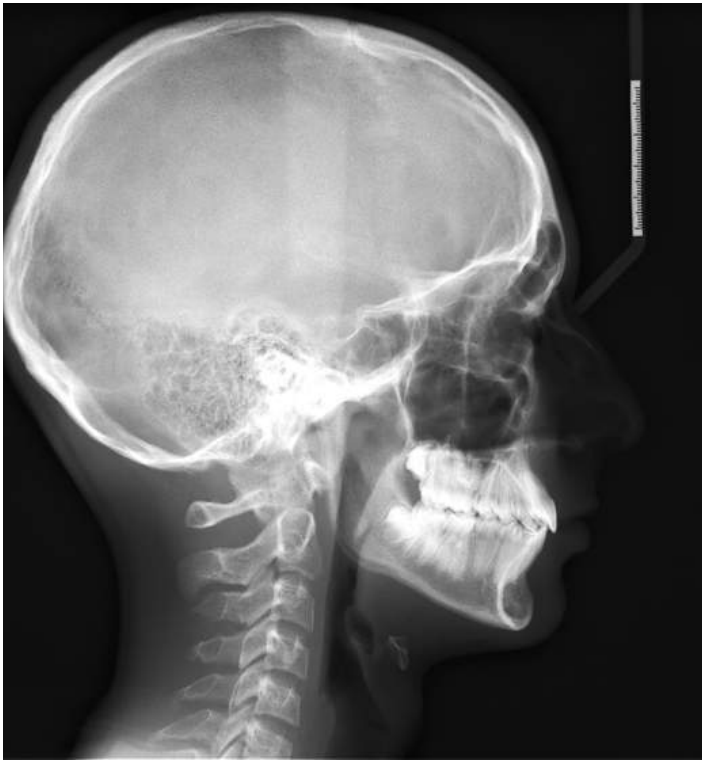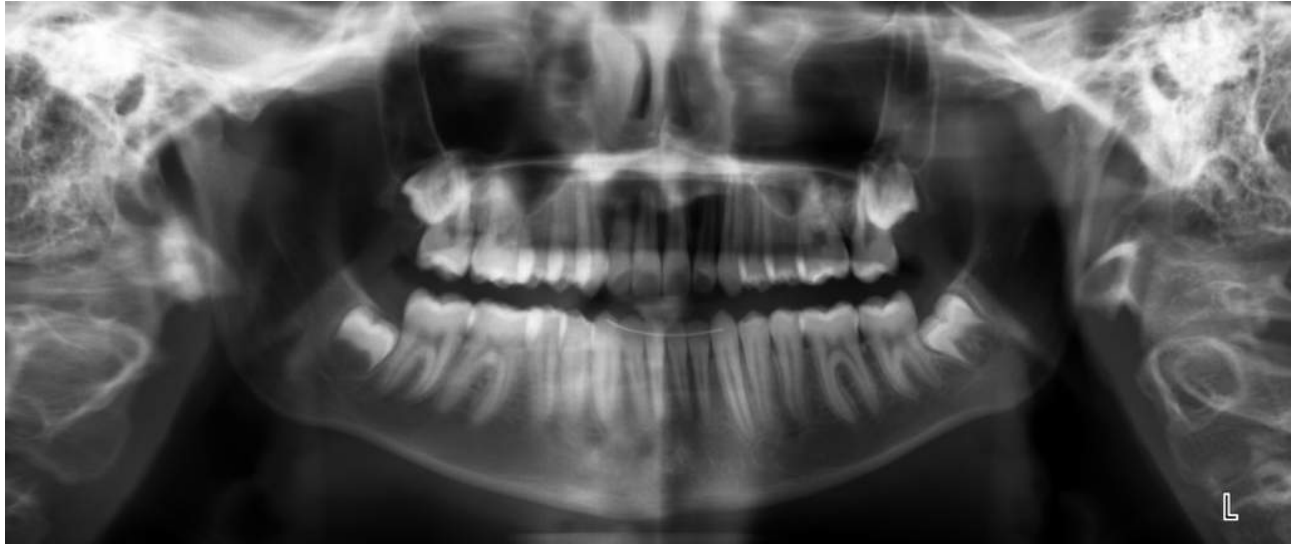After some minor rebonding,
detailing with upper .021"x.025" MB archwire and lower .021"x.025" SS archwire
and triangular vertical elastics



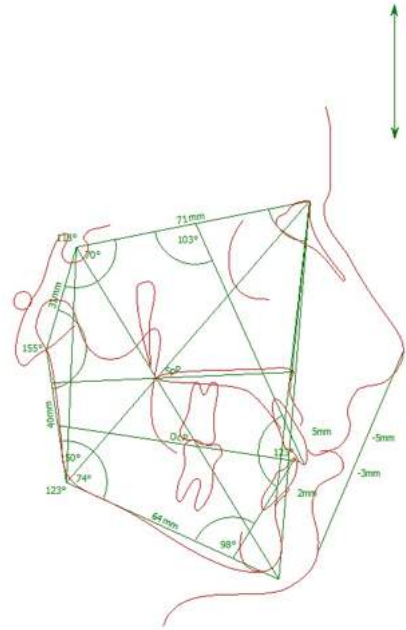
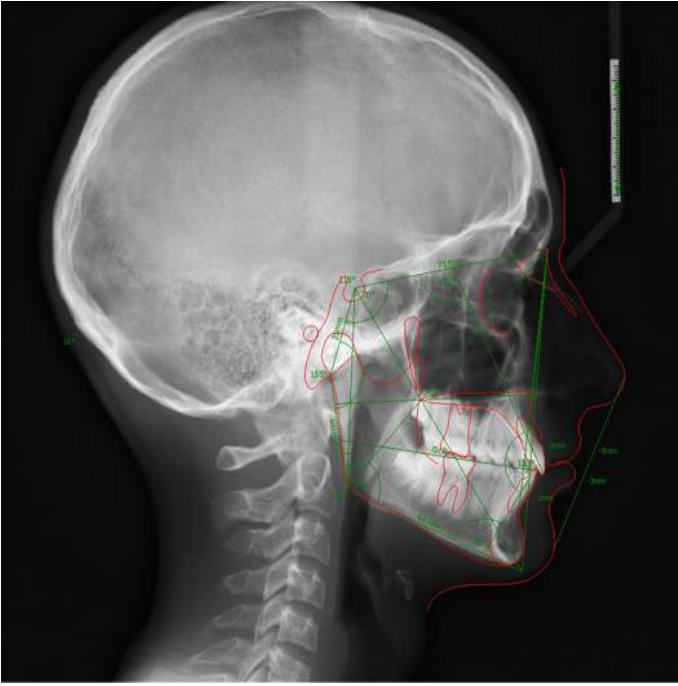
Final result after 14 months of treatment
Patient grew a lot during the treatment



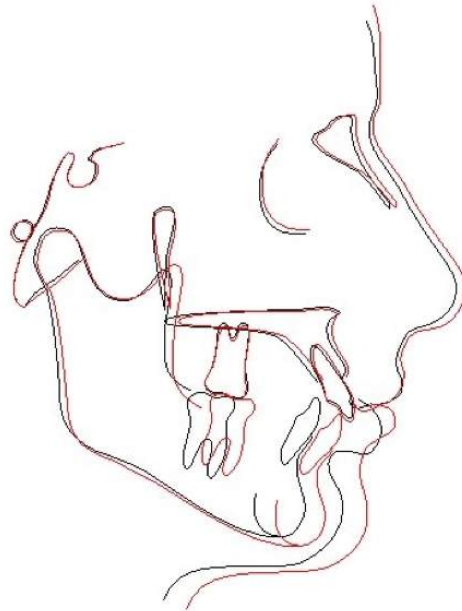
Final result after 14 months of treatment



Final xrays



Tracing and cephalometric analysis



General Superimposition